universität wien

DISSERTATION

Titel der Dissertation:

Analysis of tenascin-C expression pattern in post myocardial infarction remodelling

Verfasserin:

Mag. Barbara Thometich

angestrebter akademischer Grad:

Doktor/in der Naturwissenschaften (Dr.rer.nat.)

Wien, am:	15. Dezember 2009
Matrikelnummer:	9909083
Studienkennzahl lt. Studienblatt:	A 091 441
Dissertationsgebiet lt. Studienblatt:	Genetik - Mikrobiologie
Betreuerin:	Ao.Univ.Prof.Mag.Dr. Karin Macfelda

Dedicated to Gerald

Danksagungen

An dieser Stelle möchte ich mich recht herzlich bei allen bedanken, die diese Arbeit ermöglicht und unterstützt haben!

Univ. Prof. Dr. Udo Losert, Leiter der Biomedical Research Core Unit, möchte ich danken, für die Möglichkeit meine Arbeit hier abzuschließen.

Ein Besonderer Dank geht an unsere Gruppenleiterin, Karin Macfelda, für die ausgezeichnete Betreuung.
Ebenso möchte ich mich bei meinen Kolleginnen und Kollegen für das hervorragende Arbeitsklima und die vielen diskussionsreichen aber auch heiteren Stunden bedanken.
Ein großes Dankeschön gilt Barbara Kapeller, die immer eine Antwort auf jede Frage und immer eine Lösung für jedes Problem hat.

Bei Bruno Podesser und seinem Team möchte ich mich bedanken für die Initiation dieses Projektes, besonders bei Christoph Inci, der im Labor nicht zu ersetzen ist.

Prof. Dr. Reginald Bittner, Dr. Wolfgang Schmidt und ihrem Team möchte ich für die gute Kooperation und Hilfe im Sequenzierungs-Projekt danken.

Meinen Freunden danke ich für die vielen guten Gespräche und ihre Geduld.

Am Schluss möchte ich mich bei meinen Eltern bedanken, die mir das Studium ermöglicht haben, und bei meinem Freund Gerald, der mir immer wieder neue Kraft gibt und mein Leben bereichert.

Abstract

Tenascin-C (TN-C) is a component of the extracellular matrix (ECM) and member of the matricellular protein family. Matricellular proteins have a special role to influence cellular function and matrix composition. Those proteins bind to cellular receptors, modulate gene expression and regulate activity of various growth factors, cytokines, and proteinases. Therefore, composition of the ECM is a very dynamic network. TN-C plays an important role during embryonic development in numerous organs, e.g. in the heart. In the adult, healthy organism TN-C expression is highly restricted to a few regions, such as myotendinous junctions, gut, skin and lymphopoietic organs. Under pathological conditions, such as tumour formation, wound healing, infection, inflammation, atherosclerosis, mechanical stress, and during tissue remodelling TN-C expression is up-regulated once again.

In healthy, adult myocardial tissue TN-C is not expressed but up-regulation starts under pathological conditions, such as myocardial infarction (MI), myocarditis, and dilated cardiomyopathy. After MI TN-C is mainly expressed by fibroblasts and up-regulated in the border zone between infarcted and non-infarcted region of the left ventricle within 24 hours.

TN-C plays a dual role in cardiac healing post MI: On one hand, TN-C is important in loosen strong adhesion of cardiomyocytes and helps to rearrange surviving cells in the infarcted region. Myofibroblasts were recruited and production of matrix components is stimulated to strengthening the cardiac matrix. The elastic properties of TN-C may also help to resist the increased mechanical loading to which the border zone of the infarct is subjected. On the other hand, TN-C may loosen cardiomyocytes from the ECM, causing slippage of cardiomyocytes and supports invasion of inflammatory cells. Additionally TN-C up-regulates matrix metalloproteinases (MMPs), promotes ECM degradation and loosen cardiac tissue, which leads to an increasing risk of wall thinning, cardiac dilatation and left ventricle rupture.

The aim of this thesis was to investigate TN-C regulation post MI and to study the temporal and spatial expression pattern in an experimental MI animal model. Eight time points during the early phase post infarction (0.5, 1, 2, 3, 5, 7, 10, and 14 days post MI) were analysed and compared to a sham operated control group. At each time point samples were collected for histological and molecular biological analysis

(real time-PCR, PCR, western blot and sequencing). First, the complete, until now unknown, rat cDNA TN-C sequence (GenBank, EU596506) encompassing an open reading frame of 6.057bp was sequenced. The experiments showed that different TN-C isoforms were up-regulated at different time points post MI. Those isoforms differ in size, because of alternative splicing processes within the fibronectin type III (FN-III) domain. Overall a time dependent isoform shift could be shown and 4 different isoforms, with none, 1, 2, and 5 FN-III domains, which are up-regulated post MI were identified.

Small TN-C (TN-C_S) isoforms, which exhibit none or only a few FN-III domains in the alternative spliced side, are present within `normal´ and healthy ECM. In contrast, large TN-C (TN-C_L) isoforms are up-regulated under pathologic conditions.

Those facts suggest that the function of different spliced TN-C isoforms can be regulated through a time dependent shift during tissue remodelling processes post MI.

Keywords: tenascin C, myocardial infarction, remodelling, fibroblasts, alternative splicing, isoforms

Zusammenfassung

Das Protein Tenascin-C (TN-C) ist Bestandteil der extrazellulären Matrix (EZM) und gehört zur Familie der matrizellulären Proteine. Matrizelluläre Proteine beeinflussen wichtige Zellfunktionen und den Aufbau der EZM. Sie binden an zelluläre Rezeptoren, modulieren die Genexpression und regulieren die Aktivität von verschiedenen Wachstumsfaktoren, Zytokinen und Proteinasen. Die EZM stellt somit ein sehr dynamisches Netzwerk dar. Während der Embryonalentwicklung spielt TN-C in vielen Geweben, wie zum Beispiel dem Herzen, eine wichtige Rolle. Im adulten, gesunden Organismus wird TN-C nur sehr lokal, wie etwa in den myotendinous junctions, dem Darm, der Haut und lymphatischen Organen exprimiert. Unter pathologischen Bedingungen wie z.B. bei Tumorentstehung, Wundheilung, Infektion, Inflammation, Atherosklerose, mechanischem Stress und dem Remodelling Prozess kommt es erneut zu einer Hochregulation von TN-C.

Während im adulten, gesunden Herzen das Protein nicht exprimiert wird, kommt es unter pathologischen Umständen, wie Myokardinfarkt (MI), Myokarditis oder dilatativer Kardiomyopathie, erneut zur Proteinexpression. Nach einem Myokardinfarkt ist TN-C in der Randzone zwischen infarziertem und nicht infarziertem Gewebe innerhalb von 24 Stunden detektierbar, wobei die Hauptquelle der TN-C Produktion die Fibroblasten darstellen.

TN-C spielt eine duale Rolle im kardialen Wundheilungsprozess: Auf der einen Seite kommt es durch Deadhäsion der Kardiomyozyten zu einer Umstrukturierung des infarzierten Gewebes. Myofibroblasten können leicht in das betroffene Areal einwandern und Matrixkomponenten für die Stärkung der EZM produzieren. Zudem wirkt TN-C mit seiner Elastizität der enormen mechanischen Last, die auf die Randzone des Infarktareals wirkt, entgegen. Auf der anderen Seite können Kardiomyozyten von der EZM abrutschen und inflammatorische Zellen einwandern. Matrixmetalloproteinasen (MMPs) werden verstärkt exprimiert, was zur Degradation der EZM führt. Dadurch kann es zu einer Ausdünnung des linken Ventrikels, einer Dilatation und im schlimmsten Fall zur Ruptur des Ventrikels kommen.

Im Rahmen der vorliegenden Arbeit liegt das Hauptinteresse auf dem zeitlichen und räumlichen TN-C Expressionsmuster nach einem Myokardinfarkt, welches am Rattenmodell untersucht wurde. Insgesamt wurden acht verschiedene Zeitpunkte

(0.5, 1, 2, 3, 5, 7, 10 und 14 Tage) nach Infarkt untersucht, und mit einer sham operierten Kontrollgruppe verglichen. Zu jedem Zeitpunkt wurden Proben für histologische und molekularbiologische Analysen (Real time-PCR, PCR, Western Blot und Sequenzierungen) entnommen. Zuerst wurde die gesamte, bisher unbekannte, TN-C cDNA Ratten-Sequenz mit 6.057bp (GenBank, EU596506) sequenziert. Die Untersuchungen zeigten, dass verschiedene TN-C Isoformen zu unterschiedlichen Zeitpunkten post MI vorhanden sind. Diese Isoformen kommen durch alternatives Splicing der Fibronektin Typ-III Domänen (FN-III) zustande. Es wurde ein zeitlicher Shift der Isoformen nachgewiesen und insgesamt 4 verschiedene Isoformen, mit keiner, 1, 2 und 5 FN-III Domänen identifiziert.

Es ist bekannt, dass Isoformen mit wenigen bzw. keinen FN-III in der alternativ gesplicten Region mit einer gesunden und „normalen“ EZM korrelieren, während größere Varianten mit vielen FN-III Domänen, mit pathologischen Veränderungen im Zusammenhang stehen.

Aus diesen Fakten kann man schließen, dass die Funktion der unterschiedlich gesplicten TN-C Isoformen durch einen zeitlichen Shift nach einem MI reguliert wird.

Schlagworte: Tenascin C, Myokardinfarkt, Remodelling, Fibroblasten, Alternatives Splicen, Isoformen

Table of Contents

Abstract 7

Zusammenfassung 9

1. INTRODUCTION 15

1.1. The Extracellular Matrix - Matricellular Proteins 15

1.2. The Tenascin Family 16

1.2.1. Tenascin-C 16

1.2.1.1. Expression of Tenascin-C 18

1.2.1.2. Degradation of Tenascin-C 19

1.2.2. Tenascin-R 21

1.2.3. Tenascin-X 21

1.2.4. Tenascin-Y 21

1.2.5. Tenascin-W 22

1.3. Structure of Tenascins 22

1.4. Tenascins - Isoforms, Domains and Function 24

1.4.1. Tumour Development 29

1.4.2. Wound Healing 30

1.5. Myocardial Infarction 31

1.5.1. Cardiac Remodelling and Repair Mechanisms Post Infarction 32

1.5.2. Biomarkers - Laboratory Diagnosis of Myocardial Infarction 34

1.6. Tenascin-C in the Heart 37

1.6.1. Tenascin-C in Early Heart Development 37

1.6.2. Tenascin-C in Myocardial Remodelling 38

1.6.2.1. Tenascin-C in Post Myocardial Infarction Remodelling 38

1.6.2.2. Tenascin-C in the Heart Failing Process 41

1.7. Medical Applications of Tenascin-C 43

Aim of the thesis 45

2. MATERIAL AND METHODS *47*

2.1. Animal Model of Myocardial Infarction **47**

2.2. Sample Preparation **49**

2.3. RNA Isolation **50**

2.4. Protein Isolation **51**

2.5. cDNA Synthesis **51**

2.6. PCR **52**

2.7. Sequencing **54**

2.8. Real Time-PCR **54**

2.9. Histological and Immunohistochemical Analysis **56**

2.9.1. H&E Staining and Infarct Size Measurement 56

2.9.2. Trichrome (Goldner) Staining 56

2.9.3. TN-C Staining 57

2.10. Polyacrylamide Gel Electrophoresis and Western Blot Analysis **58**

2.10.1. Sample Preparation 58

2.10.2. Buffers and Solutions 60

2.11. Statistical Analysis **61**

3. RESULTS *63*

3.1. Sequencing Results **63**

3.2. PCR Results **66**

3.3. Real Time-PCR Results **67**

3.4. Histological and Immunohistochemical Analyses **69**

3.4.1. Morphometric Studies 69

3.4.2. TN-C and Trichrome (Goldner) Staining 75

3.4.3. TN-C Staining of Control Organs 81

3.5. Western Blot Results **84**

4. DISCUSSION *87*

4.1. Sequencing Results 87

4.2. PCR Results 89

4.3. Real Time-PCR Results 90

4.4. Histological and Immunohistochemical Analysis 90

4.4.1. Morphometric Studies 90

4.4.2. TN-C and Trichrome (Goldner) Staining 91

4.4.3. TN-C Staining of Control Organs 93

4.5. Western Blot Results 95

4.6. Knockout Mice 96

4.7. Tenascin-C - A Potential New Biomarker? 97

4.8. Limitations of the Study 98

5. CONCLUSION *99*

6. REFERENCES *101*

7. ABBREVIATIONS *115*

8. APPENDIX *119*

8.1. Rat TN-C: cDNA Sequence 119

8.2. Rat TN-C: Translation 121

9. CURRICULUM VITAE *123*

10. PUBLICATIONS *125*

1. INTRODUCTION

1.1. The Extracellular Matrix - Matricellular Proteins

Specialised cells of developing multicellular organisms are embedded in a complex extracellular matrix (ECM). The ECM regulates the dynamic cell environment and affects cellular processes including cell growth, differentiation, migration, survival as well as wound healing and fibrosis.
Major components of the ECM are different types of collagens, proteoglycans, and glycoproteins, which are produced intracellular by resident cells, secreted outside the cells and assimilate into the existent ECM. Additionally the ECM contains many growth factors, cytokines, proteinases, and a lot of other bioactive molecules that interact with the cell surface [1].
Therefore, the complex composition of the ECM serves many functions, such as cellular anchorage, intercellular communication, and flexibility of mature tissues.

During the last 15-20 years, increasing attention turned to matrix proteins, which modulate cell function but do not appear to have a direct structural role within the ECM. These proteins have been termed matricellular proteins to accentuate their special role to influence cell function. Matricellular proteins regulate cellular function and matrix composition by binding to their cellular receptors and by modulating expression and activity of growth factors, cytokines, and proteinases [1, 2].
In cardiac tissue, matricellular proteins include, thrombospondin-1 (TSP1), thrombospondin-2 (TSP2), osteonectin (also known as BM-40 or SPARC = secreted protein acidic and rich in cystein), osteopontin (OPN), tenascin-X (TN-X), and in particular tenascin-C (TN-C) [3].

1.2. The Tenascin Family

The tenascin (TN) family includes five proteins (shown in *Figure 1.*): TN-C, TN-R, TN-X, TN-Y and TN-W [4, 5].

TN protein expression appears highly restricted and shows dynamic pattern during embryonic development, particularly during neural development, organogenesis, skeletogenesis, and vasculogenesis. However, each TN exhibits a specific expression pattern and localisation of expression overlap only in parts.

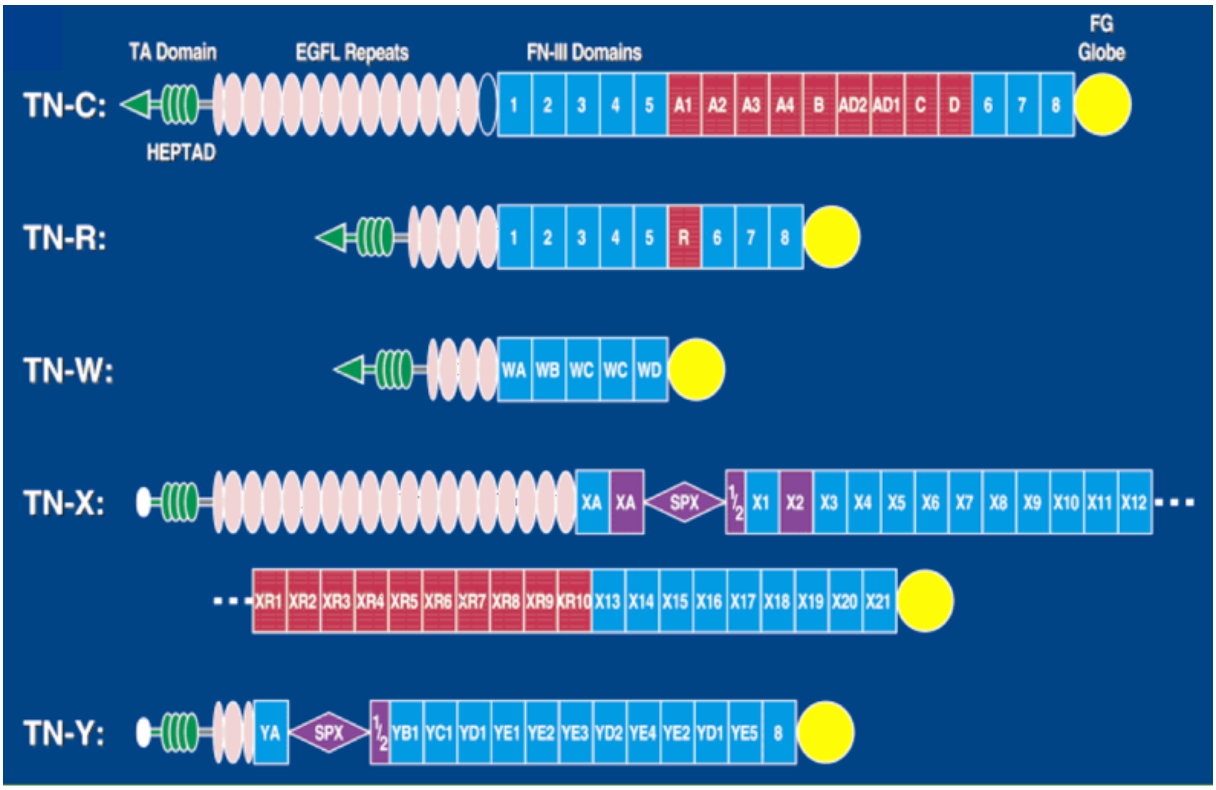

Figure 1. *Schematic diagram of all members of the tenascin family (TA domain = tenascin assembly domain, EGF-L repeats = epidermal growth factor like repeats, FN-III domains = fibronectin type III domains, FG = fibrinogen globe) [5].*

1.2.1. Tenascin-C

The hexameric protein TN-C (shown in *Figure 2.*) was discovered simultaneously in a number of laboratories in the early 1980s.

The name `tenascin´ originated from the ability as adhesion protein (from the latin `tenere´ = to hold) and its known association to a variety of `nascent´ tissues (`nacsi´ = to be born) [6, 7].

The protein was first called TN-C in 1986 by Chiquet-Ehrismann et al. [6], but in the last twenty years TN-C was given a number of different names including: glial/mesenchymal extracellular matrix protein (GMEM) [8], myotendinous antigen [9, 10], hexabrachion [11], cytotactin [12], J1 $_{220/200}$ [13], tenascin [6], and neuronectin [14]. After detecting other proteins belonging to the TN family, the `C´ from TN-C reminds of cytotactin - one of the first names of the protein.

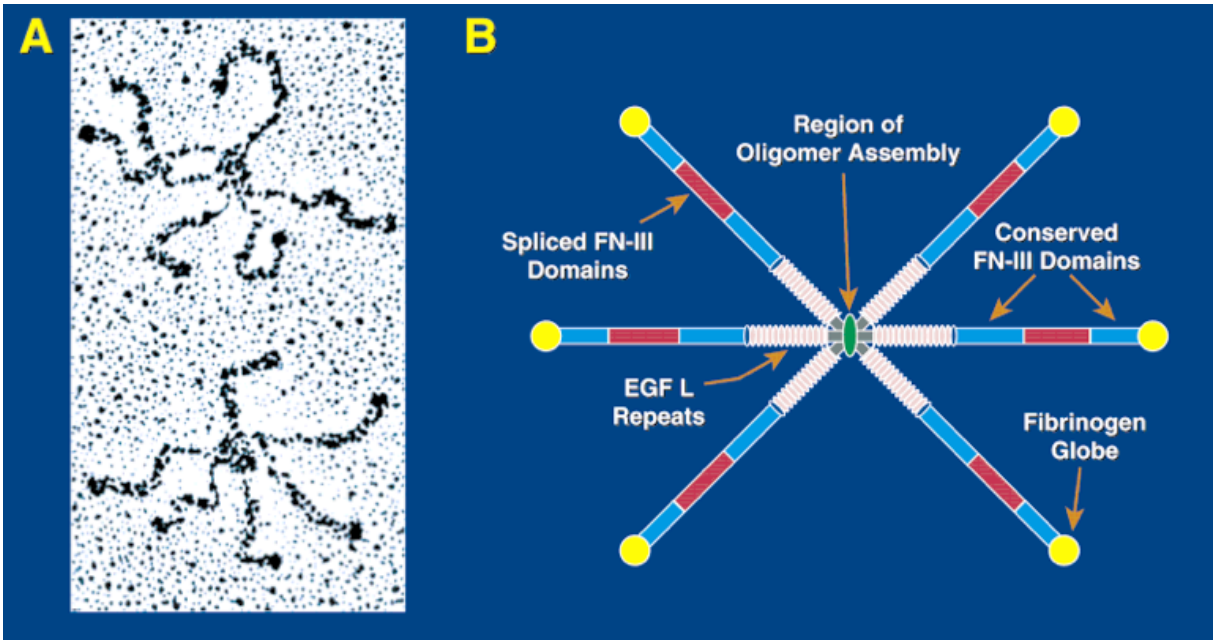

Figure 2. (A) *Image of two mouse TN-C molecules. Each arm is approximately 100nm in length.* ***(B)*** *Schematic model of hexameric TN-C structure (EGF-L repeats = epidermal growth factor like repeats, FN-III domains = fibronectin type III domains) [5].*

In 1984 Chiquet-Ehrismann et al. described a monoclonal antibody M1 called `myotendinous antigen´ [9, 10], which recognises an ECM component expressed in myotendinous junctions, within the perichondrium during early chicken embryogenesis and in developing ligaments and tendons. In 1986 Chiquet-

Ehrismann et al. renamed this protein as TN-C. It was demonstrated that TN-C is selectively present within the mesenchyme, surrounding fetal rat mammary glands, hair follicles, teeth, three organ anlagen, and additionally associated with mammary tumours [6].
From 1986 to 1988 Erickson and Taylor [15], Hoffmann et al. [16] and Chiquet-Ehrismann et al. [6] postulated simultaneously that TN-C is identical to the GMEM defined by a monoclonal antibody which was described in 1983 [8]. The 1984 characterised protein hexabrachion [11] and the 1985 descript molecule cytotactin [12], were also identical with TN-C. Furthermore, the J1-antigen descript in 1985 [13] showed homologies to TN-C.

Particularly, selectively TN-C up-regulation in epithelial-mesenchymal junction in embryonic development produced interest.
In 1988 it was demonstrated in mesenchyme from small intestine, where reciprocal mesenchymal-epithelial interaction is known to be important for gut morphogenesis, that the appearance of TN-C in the mesenchyme was dependent on the presence of epithelium [17].

1.2.1.1. Expression of Tenascin-C

In adults, TN-C expression is normally restricted to a few areas. TN-C is found in musculoskeletal regions in which high mechanical forces are transmitted from one tissue component to another, for example from muscle to tendon and from tendon to bone [18]. Furthermore, TN-C is present interstitially in a variety of tissues such as parts of the brain, gut, skin, and lymphopoietic organs [19].

However, under specific pathological conditions such as inflammation, wound healing and tumourgenesis, TN-C re-expression is observed [7]. Especially in tumour tissue TN-C is extremely up-regulated [19].
TN-C expression can be induced by a variety of pro- and anti-inflammatory cytokines and interleukins such as IL-1/4/6/8/13, tumour necrosis factor α (TNF-α), interferon γ (IFN-γ), and growth factors such as epidermal growth factor (EGF), transforming

growth factor β (TGF-β), connective tissue growth factor (CTGF), platelet-derived growth factor-BB (PDGF-BB), Lif-1, and NfκB (nuclear factor kappa-light-chain-enhancer of activated B cells) [14, 20, 21]. In addition, hypoxia, reactive oxygen species (ROS), and mechanical stress, which plays an essential role in tumour tissue, also induce TN-C expression [22].
Ras protein/MAPK (rat sarcoma protein/mitogen-activated protein kinase) and Wnt can result in TN-C expression and, interestingly, both of these signalling pathways are induced by TN-C. This mechanism suggests a positive feedback regulation of TN-C expression and responses to TN-C in tumours [22].
Activation of reporter constructs under control of the human TN-C promoter suggests that signalling leads to activation of a cascade of prominent transcription factors. Those factors, involved in activation of TN-C gene transcription, include TCF/LEF (T-cell-specific transcription factor/lymphoid enhancer-binding factor), NfκB, c-Jun, Ets, Sp1, and Prx-1 [22-24].

A variety of molecules have been identified as receptors for TN-C include members of the integrin family, contactin/F11, which is a cell adhesion molecule belonging to the immunoglobulin superfamily, annexin II, a receptor tyrosine phosphatase, and cell surface heparan sulfate proteoglycans [7, 25].

It is noticeable that TN-C expression is so tightly controlled in normal and healthy tissue homeostasis, because of the high number of factors that induce TN-C expression.

1.2.1.2. Degradation of Tenascin-C

TN-C is degraded by members of the matrix metalloproteinases (MMP) family in numerous of tissues [7]. TN-C deposition coincides with the expression and activity of matrix MMPs and, furthermore, MMPs and TN-C are regulated by a reciprocal mechanism [5].

In healthy adult cardiac tissue different MMPs, including collagenases (MMP-1, MMP-13, and MMP-8), gelatinases (MMP-2 and MMP-9), stromelysins (MMP-3 and

MMP-7) and membrane-type MMPs (MMP-14) are expressed.
Additional all 4 tissue inhibitors of matrix metalloproteinases (TIMP-1, TIMP-2, TIMP-3 and TIMP-4) have been identified within the normal human myocardium [26].

Within the heart it has been shown that MMP distribution may be also `chamber specific´. For example, the relative level of MMP-1 is lower in the right ventricle compared to the left ventricle.
This chamber specific MMP appearance results from a combination of factors including different loading conditions, embryological origin, and cellular response to biological stimuli [26].

Studies with rat and mouse MI models as well as tissue samples from patients undergoing emergent cardiac surgery showed mainly increased levels of MMP-2 and MMP-9 [26].
Expression of MMPs lead to a reorganisation of pre-existing ECM and provide a modified tissue microenvironment, promoting cell migration, growth, survival, and differentiation [5].

TN-C is known to induce MMP expression, for example large TN-C isoforms, with many FN-III domains in the splicing region, up-regulate MMP-1 through a MAPK pathway in human chondrosarcoma cells [27].
Small TN-C isoforms, with none or only a few FN-III domains, can be cleaved enzymatic by MMP-7 by removing the NH_2-terminal knob. The large isoform shows the same MMP-7 sensitive site, but is further degraded in the splicing area by MMP-2 and MMP-3 [28, 29]. However, the sole site susceptible to proteolytic cleavage by MMP-2 and MMP-3 is found within the FN-III A3 domain (*Figure 1.*). Therefore, small TN variants are resistant to MMP-2 and MMP-3 degradation and large isoforms are susceptible to this digestion. It seems to be that all TN-C isoforms are resistant to MMP-9 [28, 29].

Alteration in amount and relative level of MMPs and TIMPs results in a modified composition of the myocardial matrix. This change affects the overall heart structure, geometry, and function [30].

1.2.2. Tenascin-R

Tenascin-R (TN-R) also called restrictin, janusin or $J1_{160/180}$, is - in contrast to TN-C - a trimeric molecule and exclusively synthesised within the central nervous system (CNS), where it is mainly produced by oligodendrocytes. It is a major component of brain ECM during development and persists in the adult organism only in some regions of CNS [31].

1.2.3. Tenascin-X

Tenascin-X (TN-X) was discovered, because of its opposite overlapping orientation with the 21-hydroxylase gene (CYP21B), located in the central region of human major histocompatibility complex-III (MHC) locus [32, 33].
TN-X is widely expressed during embryogenesis, but also persists after birth in adults. Fibroblasts are the major source of expression within connective tissue of the myocard, skeletal muscle as well as in the dermis of skin [12,13].
Interestingly, TN-X distribution is distinct and often reciprocal to that of TN-C, for instance in embryonic day 15.5 (E15.5) mouse skin and digestive tract, especially oesophagus, gut, and stomach [34].

TN-X is the first member of the TN-family whose deficiency has been clearly associated with a pathological disorder in humans called Ehler-Danlos Syndrome (EDS). This connective tissue disorder is affecting 1 in 5.000 individuals and is associated with fibrillar collagen defects causing a connective tissue disorder involving skin and joint hyperflexibility, vascular fragility, and poor wound healing [35]. In most patients, bruising has been a prominent feature. In mice inactivation of the TN-X gene caused a syndrome similar to the EDS in human [3, 36].

1.2.4. Tenascin-Y

Tenascin-Y (TN-Y) is a protein expressed in chicken and most closely related to mammalian TN-X. Both, TN-Y and TN-X, belong to the largest proteins of TN family

and are predominantly expressed in cardiac tissue and skeletal muscle, where they are up-regulated in muscle-associated connective tissues [37, 38].
TN-Y expressed in skin shows a complementary expression pattern to TN-C, whereas within the lung and kidney the sites of expression are partly overlapping. TN-Y is also present in embryonic skeletal muscle, where it is expressed in developing connective tissue between muscle fibres [37].

1.2.5. Tenascin-W

The youngest and smallest member of the TN family is, tenascin-W (TN-W), which was first described in 1998 by Weber et al. in zebrafish [39]. In 2004 Scherberich et al. described the murine orthologue of zebrafish TN-W [40]. TN-W is expressed prominently during palate formation, osteogenesis and smooth muscle development. In the adult organism, TN-W is found within the kidney, cardiac semilunar valves, corneal limbus and periosteum. Expression pattern showed often a co-localisation with TN-C during several early developmental stages [40].

1.3. Structure of Tenascins

All TNs include a common set of structural motives and has been shown to be highly elastic. Proceeding in carboxyl terminal direction, the domains (shown in *Figure 3.)* are stringed as follows:

- the tenascin assembly (TA) domain (shown in green),
- a linear array of epidermal growth factor-like (EGF-L) repeats (pink domains),
- two different types of fibronectin type III (FN-III) domains: conserved domains in all variants of TN-C (shown in blue) and domains that are alternatively spliced (red domains), and finally
- the carboxyl terminal fibrinogen globe (FG, yellow circle) [5].

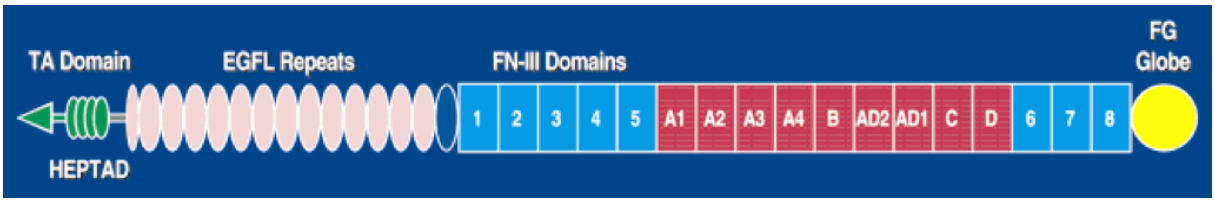

Figure 3. *Schematic diagram of TN-C structure (TA domain = tenascin assembly domain, EGF-L repeats = epidermal growth factor like repeats, FN-III domains = fibronectin type III domains, FG = fibrinogen globe) [5].*

Even if the structural motives are similar in all five known TNs, domain composition differs quite a lot. TN structure composition also varies among different species. Human and mouse TN-C contains 14½ EGF-L repeats whereas in chicken TN-C only 13½ domains exist [41]. One common feature is the terminal fibrinogen globe, which equals in all TNs. TN-C, TN-R, and TN-W contain at the amino terminal cysteine residues (green triangles) that may allow these molecules to form oligomers, like trimers, hexamers or nonamers (shown in *Figure 1.).* In contrast, TN-X and TN-Y appear to lack these residues (white circles) required to stabilise the linkage of trimers to form oligomers [5].

Human TN-C consists of 14½ EGF-L repeats and 17 FN-III domains, 8 constant expressed domains and between the fifth and sixth constant domain, 9 domains where alternative splicing occurs, named A1, A2, A3, A4, B, AD2, AD1, C, and D (*Figure 3.*). The AD of the AD1 and AD2 stands for additional domains.
In contrast, mouse (A1, A2, A4, B, C, and D) and chicken (A, B, AD2, AD1, C, and D) TN-C only has up to six domains in the splicing region [31]. TN-C sequence motives in different species display a high degree of homology, which reaches 95% for analogous FN-III domains.
TN-C covers six polypeptide chains (shown in *Figure 2.*), which are linked at their amino termini via TA domain [5, 42]. Assembly of this hexamer structure is a co-translational two-step process [31]: In the first step trimer formation is initiated by three single monomers linked together to form a triple-stranded coiled coil. In the second step, two TN-C trimers join to form a hexamer, which is stabilised by disulfide bonds between cysteine-residues in the subunits [43].

TN-R includes 4½ EGF-L repeats and either 8 or 9 FN-III repeats. The extra FN-III domain (R domain) is alternatively spliced comparable with TN-C [5].

TN-W shows the same composition of typical modules like all other members of the TN family, but no TN contains as few of them as TN-W: 3½ EGF-L repeats and 5 FN-III domains (WA-WD) in zebrafish. Mouse TN-W contains 9 FN-III repeats instead of 5 in the zebrafish orthologous [40]. Isoforms from alternative spliced molecules have not been reported for zebrafish TN-W.

The largest protein, TN-X, contains 18½ EGF-L repeats and at least 33 FN-III repeats. The FN-III repeats in TN-X fall into three different categories, which are related to another: X1-21 repeats that have not been shown to undergo alternative splicing. XA repeats, near the amino-terminal end of the array that are more related to one another and the XR1-XR10 alternatively spliced region [5].
Additionally, TN-X contains an unusual serine-proline rich (SPX) domain that was originally found in TN-Y [38].
Comparison of human, mouse, and bovine TN-X sequences showed that the second XA repeat, the SPX region with ½ of an FN-III repeat, and the X2 repeat can be alternatively spliced.

TN-Y contains a heptad repeat a small EGF-L region containing one complete and 2 ½ EGF-L repeats, an SPX-½FN-III domain, which is similar to that in TN-X and 12 FN-III repeats [5].

1.4. Tenascins - Isoforms, Domains and Function

The diversity of TN-C isoforms represents an important mechanism to alter cell signalling and downstream functions by modulating binding interactions with different receptors or other components of the ECM.
Alternative splicing of FN-III domains generates multiple TN-C isoforms. Those isoforms vary in number, in a species- and also in a cell type dependent manner [44]. In contrast, EGF-L repeats are expressed in the same way and do not alter in number in all isoforms.

Splicing of FN-III domains can be influenced by many factors including extracellular pH [45], TGF-β1 [46], and basic fibroblast growth factor (bFGF) [47, 48].

Fischer et al. demonstrated the function of different TN-C domains by deleting them from an intact chicken TN-C molecule (shown in *Figure 4.)* and scored for change in activity [49].

Tenascin-C variants	Cell adhesion		Inhibition of adhesion to Fn	Neurite outgrowth 8 h	Neurite outgrowth 24 h
TN 190	—	—	+++	—	++
TN EGF⁻	+	○	++	—	+
TN FN⁻	++	○	+	+	++
TN FB⁻	—	—	—	—	—
TN FF⁻	++	△	—	++	+++
TN EFN⁻	+	△	—	+	++

Figure 4. *Summary of functional characteristics of TN-C domains in recombinant molecules. Each variant is scored for promotion of cell adhesion by -, + or ++. Cell shape is indicated by ○ if the majority of the cells were round and by △ if the majority of the attached cells were spread. Activities in inhibiting adhesion to fibronectin (Fn) or the promotion of neurite outgrowth at two time points, 8h or 24h after plating, are indicated by -, +, ++, or +++ (TN 190 = intact TN-C, EGF = epidermal growth factor like repeats, FN = FN-III repeats, FB = fibrinogen globe, FF = FN-III repeats and fibrinogen globe, EFN = EGF-L repeats and FN-III repeats) [49].*

In single mutant molecules all EGF-L repeats, all FN-III repeats, or the FG were deleted. In double mutants the FN-III repeats were deleted together with either the EGF-L repeats or the FG, respectively. All TN-C variants were able to form correct hexameric molecules. In cell culture, intact TN-C and the mutant missing the FG did

not promote adhesion of chicken embryo fibroblasts. In contrast, molecules containing only the FG or the EGF-L repeats, were adhesive substrates and even supported cell spreading [49].

Exceptionally, the fibrinogen globe holds a crucial function in promoting interaction of TN-C to cells. Without this initial binding step, the activities of all other TN-C domains are precluded. The EGF-L repeats have cell adhesion and neurite outgrowth stimulating function, which in the context of the FN-III repeats are counteracted [49].
For this reason it is not surprisingly, that expression of larger TN-C variants, including FN-III repeats, has been correlated with increased cell migration [50], tissue remodelling [51], and invasiveness of carcinomas [52], whereas smaller molecules are expressed within more quiescent tissues and are associated with the production of a stable ECM.
Numerous experiments have shown the connection between a specific domain and their function (*Figure 4*.) and respectively, a domain and the specific binding molecule or receptor *[49]*. Unfortunately, only a few domain interactions were described in detail (*Figure 5*.) *[53]*.
The third FN-III type repeat contains a specific cell binding site, the RGD motive (amino acids: R = arginine, G = glycine, D = asparagine), to interact with the adhesion-promoting $\alpha v\beta 3$ integrin (*Figure 5.)* [54]. The alternatively spliced A-D FN-III domains (shown in red) bind the protein annexin II, and are considered in certain cell types to be counter adhesive, due to its ability to disrupt focal adhesions [55].
In addition, the TN-C isoforms with excluded A-D FN-III domains differentially bind F11 contactin through the fifth and sixth FN-III domain. These TN-C molecules bind to fibronectin (FN) with higher affinity than the larger molecules, which include the A-D domains. They are principal expressed in tissues characterised by the presence of an abundant ECM [56].

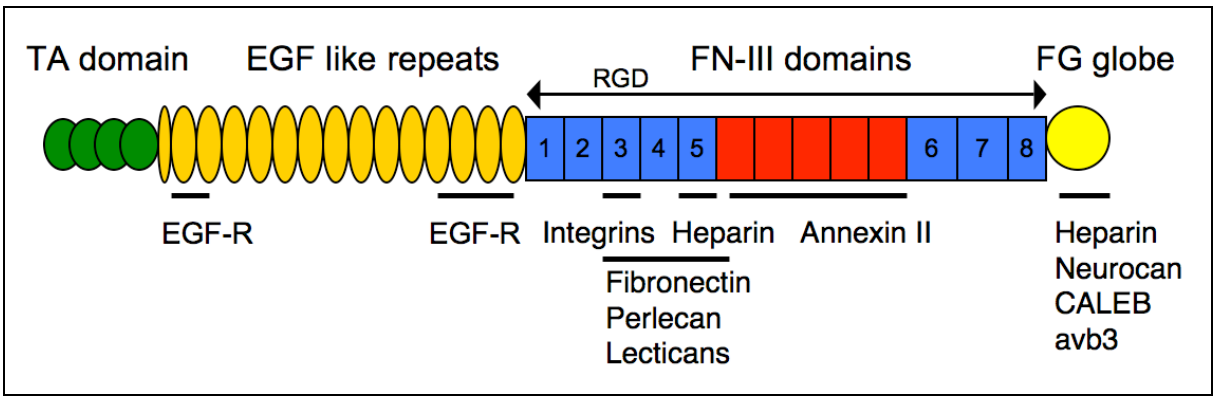

Figure 5. *Localisation of functional domains and interaction sides of mouse TN-C (TA domain = tenascin assembly domain, EGF-L repeats = epidermal growth factor like repeats, FN-III domains = fibronectin type III domains, FG = fibrinogen globe, RGD motive: R = arginine, G = glycine, D = asparagine) [53].*

Perlecan, which supports the maintenance of the endothelial barrier and vascular homeostasis, binds to TN-C via its FN-III domains 3-5, whereas the alternatively spliced A-D domains of TN-C inhibit this interaction (*Figure 5.*) [5, 44].
In addition there may be a heparin binding site in the last FN-III domain of the alternative spliced region [55]. Other FN-III repeats as well as EGF-L repeats may mediate other cellular interactions including cell proliferation, neural cell adhesion, and immune modulation.

In cell culture studies it was shown that TN-C specifically interacts with fibronectin. TN-C can bind to the FN-III 13 of the Hep-II site, thereby blocking cell binding to fibronectin through syndecan-4. This can cause enhanced proliferation of human glioblastoma and breast carcinoma cells that could be neutralised by the addition of recombinant FN-III 13 as well as by over-expression of syndecan-4 [57]. The FN-III domains 1-3 support binding, growth, and differentiation of postnatal day 6 (P6) cerebellar neurons in culture after 24 hours. Whereas the EGF-L domains and the alternatively spliced FN-III A1, A2, and A4 domains showed anti-adhesive properties on CNS neurons. Neurite outgrowth-promoting properties could be assigned to the alternatively spliced FN-III domains B, D, and domain 6. These findings suggest, that the developmental regulation of alternative splicing is functionally significant in CNS [58].

Aortic smooth muscle cells (ASMC) expressed in response to injury an isoform containing only the FN-III domains A1 and A2. This isoform is up-regulated in aortic cells of newborn rats by stimulation of PDGF-BB, which is a potent chemo-attractant. In SMCs, derived from adult rat aorta, the expression of this isoform is markedly down-regulated [59].
Under cell culture conditions the recombinant A1-A2 protein promoted SMC chemotaxis but not adhesion or proliferation, which suggests a new role of this specific TN-C isoform in the remodelling of vascular wall [59].

Several studies pointed out, that the human large TN-C isoform inhibited attachment of both human and rat ASMC to fibronectin [21].
PDGF-BB induced TN-C biosynthesis resulting in generation of 3 different splice variants. The ability of PDGF-BB to up-regulate the expression of TN variants may cause destabilisation of interactions between cells and ECM and promote cellular migration [21].

In mouse brain 27 different TN-C isoforms were identified [47]. The AD1 and AD2 domains, which were present in human and chicken TN-C, were complete absent in mouse brain tissue. The A3 domain might be unique for primate TN-C. Whereas the human AD1 [60] and AD2 [61] domains were often in association with tumour formation.
Tissue from P6 mice cerebellum compared with brain tissue without cerebellum showed a higher level of TN-C in brain tissue containing cerebellum. This observation stands in agreement with resent findings that the P6 cerebellum is the main source of TN-C mRNA in mouse brain, expressing different isoforms with 1 up to 6 alternatively spliced FN-III domains [47].

All FN-III domains have nearly same size (~270bp) [62] so it is necessary to analyse different isoforms with domain specific primer for PCR analysis and sequencing or antibodies in immunohistochemical (IHC) studies.

1.4.1. Tumour Development

TN-C was originally discovered in 1983 as GMEM antigen [8]. In the meantime many studies suggested a supportive role for TN-C in tumour growth, metastasis, tumour angiogenesis, and inhibition of immune surveillance. Most reports described that TN-C is involved in initiation of tumourigenesis and progression to metastasis. Furthermore, TN-C staining correlates often with tumour grade and strong immunohistochemical staining indicates in the majority of cases poor prognosis in tumour progression [22].

TN-C is highly expressed in tumour tissue in the majority of malignant solid tumours, including those arising in the brain, breast, uterus, ovaries, prostate, pancreas, colon, stomach, mouth, larynx, lung, liver, kidney, bladder, skin, bone, soft tissues, and in lymphomas [22, 63, 64].
The two main and quantitative important variants arise by complete inclusion or skip of the whole alternatively spliced region including FN-III domains A1-A4, B, AD1, AD2, C, and D. Those two isoforms are known as TN-C_S (small) and TN-C_L (large) isoform. In contrast to physiologically adult tissues, where expression of TN-C_L only rarely occurs, high expression levels can be detected in embryogenesis and during several processes of ECM remodelling including tumour progression [65].
Designative therefore, the human AD2 domain was found in 1997 by Mighell et al. in oral cancer tissue [61] and the human AD1 domain was first observed in 1993 by Sriramarao et al. in a glioblastoma cell line [60].
The mRNA expression patterns of the FN-III domains A1-A3 are very similar among the different carcinomas. Stronger alterations exist in the region from the domains B to D. In general, the domains AD1/C are rarely expressed. AD1 domain expression seems to be connected with compact invasion pattern [64].

In 1999 it was shown the first time that expression of different TN-C domains is not only dependent on tumour type but also on tumour stage [66].

1.4.2. Wound Healing

Wound healing response starts immediately after tissue injury, whereas different cells (fibroblasts and platelets) and components, such as collagens, cytokines and growth factors (e.g. PDGF and TGF-ß) are crucial during this process. However, ECM proteins, such as fibronectin and TN-C are known to be important key players in wound healing [67].
In normal skin, TN-C is sparely expressed, predominantly in association with basement membranes. In contrast, TN-C expression increases in healing wounds at the wound edge in all skin layers, extending towards the normal skin. In particular, strong TN-C specific staining is expressed at the dermal-epidermal junction beneath migrating and proliferating epidermis [68]. TN-C is present throughout the ECM of granulation tissue, which filled full-thickness wounds, but TN-C is not detectable in the scar after wound contraction is complete. Interestingly, TN-C distribution pattern is spatial and temporal different from that of FN [68].

In healing wounds dermal fibroblasts and epidermal keratinocytes are identified as origin of TN-C expression. Both cell types expressed the larger TN-C mRNA, but in contrast epidermal keratinocytes expressed additionally smaller transcripts at higher levels than dermal fibroblasts [69].
Within keratinocytes the presents of the 2 different transcripts can be up-regulated by inflammatory cytokines. Addition of IFN-γ slightly increased the level of large transcripts, whereas, TNF-α influences the expression of smaller TN-C transcripts. In contrast, IL-4 affected the expression of both, the large and small TN-C mRNAs [69].

During corneal wound healing, human corneal epithelial cells (HCE) are the origin of 2 fibronectins and TN-C_L isoforms [70]. Distribution of fibronectin and TN-C showed a distinctly different pattern in HCE cells. Fibronectin showed clear fibrillar arrangement, whereas TN-C appears as diffuse patches underneath the cells [70].
Also secretory mechanisms, comparing those two proteins, seem to bee quite different. Fibronectin is mainly present in the ECM and secreted into the culture medium, whereas TN-C is only present in the ECM [70].
Adhesion experiments showed that HCE adhere to fibronectin through distinct integrins in a process that can be modulated by TN-C [70].

In normal skeletal muscle TN-C is not present, but in cell culture studies Gullberg et al. found out that fetal muscle cells synthesise TN-C [19]. Considering this findings muscle TN-C expression was analysed, because it has been reported that TN-C is up-regulated in endomysial ECM after denervation and following trauma.
TN-C immunoreactivity was examined in muscle samples from patients with Duchenne/Becker muscular dystrophy (DMD/BMD) and myositis, both of which were characterised by muscle degeneration and various degrees of muscle regeneration. TN-C expression was markly up-regulated in DMD/BMD and in myositis, and in both diseases this correlates to macrophage invasion and T-cell accumulation [19].

1.5. Myocardial Infarction

Myocardial infarction or acute myocardial infarction (AMI) is defined as death or necrosis of myocardial cells (*Figure 6.*). It occurs when blood supply to the myocardial tissue is interrupted. The resulting myocardial ischemia is most commonly due to occlusion of a coronary artery following rupture of an atherosclerotic plaque. The resulting ischemic period if left untreated, can cause damage and/or death of the affected myocardium [71].
Myocardial infarction is the leading cause of death for both sexes all over the world. The median age of first acute MI is higher in women than men (65 versus 56 years). Apart from previous cardiovascular disease and familiar history of coronary heart diseases at young age, there are nine modifiable risk factors, standing in association with MI in women and men. Those factors include: hypertension/high blood pressure, diabetes mellitus, lack of exercise, excessive alcohol consumption, high blood levels of cholesterol: low and high density lipoprotein (LDL and HDL), tobacco smoking, ascendance, high risk diet, and chronic high stress levels [72].

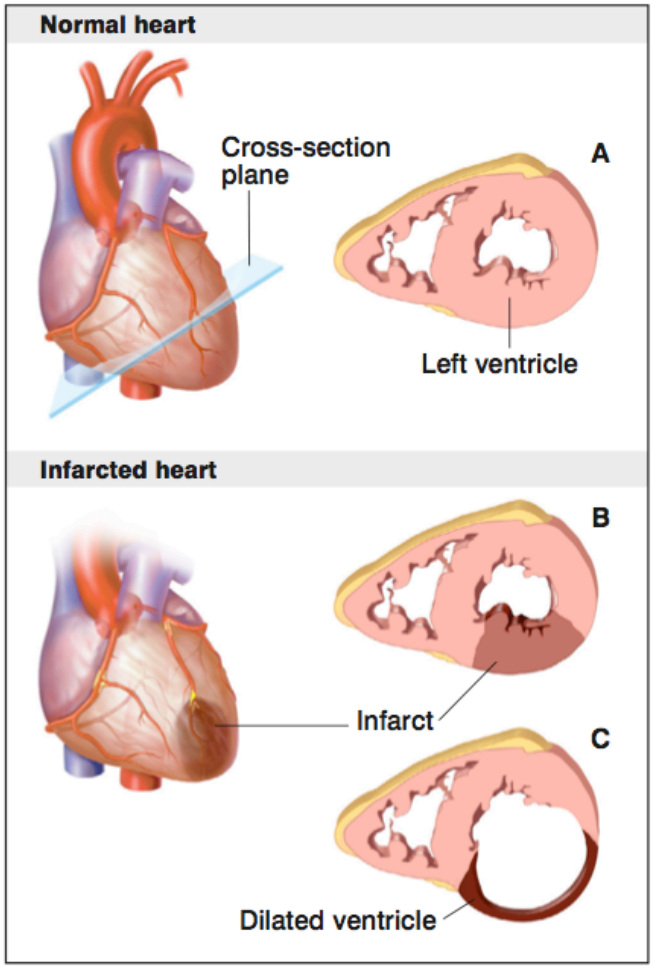

Figure 6. *Schematic diagram of the infarcted versus the healthy heart.* ***(A)*** *The left ventricle has a thick muscular wall (shown in cross-section).* ***(B)*** *After infarction cardiomyocytes in the left ventricle are deprived of oxygen and die.* ***(C)*** *This undersupply of oxygen eventually cause left ventricular dilatation and wall thinning [73].*

1.5.1. Cardiac Remodelling and Repair Mechanisms Post Infarction

The ECM in healing myocardial tissue undergoes dynamic changes that dramatically alter cell microenvironment. ECM is not only a stiff network, and the composition of the ECM plays a crucial role in regulating cellular behaviour, cell interactions through specific surface receptors, cell phenotype, and gene expression. So the ECM can resist altering mechanical properties of the left ventricle [30].

Post infarction myocardial structure, function and geometry are dramatically affected and cardiac repair mechanisms are immediately activated (*Figure 7*.).

Those mechanisms are regulated through a dynamic and precise timed dependent activation and/or repression of inflammatory pathways, followed by alteration to granulous and fibrous tissue deposition and finally the formation of a solid scar [74].

Necrosis of cardiomyocytes triggers production of pro-inflammatory cytokines and chemokine, which leads to recruitment of inflammatory cells (neutrophils, macrophages and monocytes) into the infarcted area. This repair mechanism is important for the formation of a stabilised scar, increasing the tensile strength of the wound [74]. Production of growth factors leads to fibroblast migration, proliferation and activation. Activated fibroblasts and myofibroblasts produce most of the ECM macromolecules [30]. Collagen production is up-regulated and an extensive microvascular 3D-organised network is formed. Furthermore, the renin-angiotensin-aldosterone system (RAAS) is affected, which is a hormone system regulating blood pressure and water balance [30].

Additionally, a fine balance between activated MMPs that degrade ECM components and TIMPs that inhibit MMPs action, is necessary for regulated and `normal´ remodelling and inhibit excessive matrix degeneration [30].

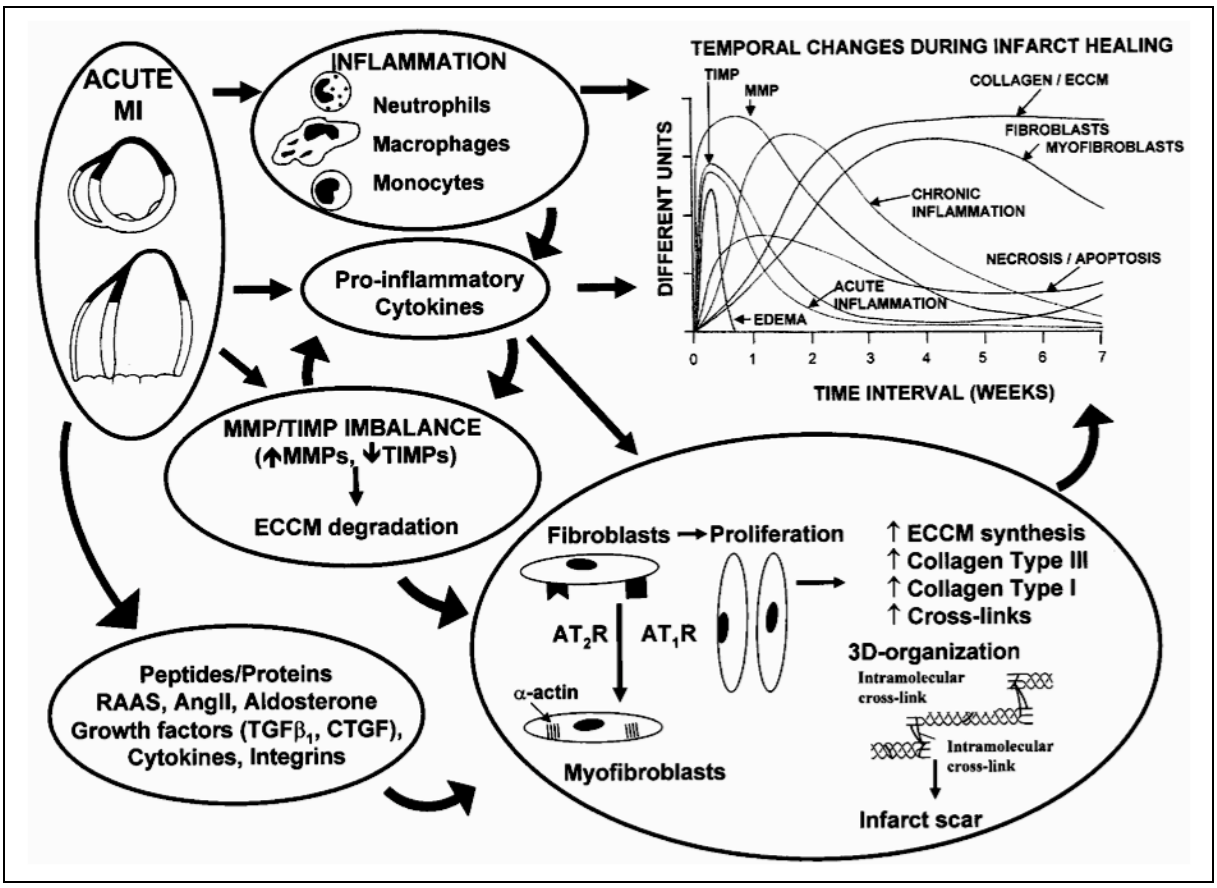

Figure 7. *Temporal changes during the healing process after myocardial infarction. Schematic showing pathways leading to formation of the infarct scar (R = receptor, RAAS = renin-angiotensin-aldosterone system, ECCM = extracellular collagen matrix, $AT_{1/2}R$ = angiotensin II type 1/2 receptor) [30].*

1.5.2. Biomarkers - Laboratory Diagnosis of Myocardial Infarction

Serum/blood biomarkers have become the `gold standard´ for MI diagnosis. Morrow and de Lemos have set out three criteria a biomarker should fulfil to be useful clinically [75]: (1) Can the clinician measure it? (2) Does it add new information? (3) Does it help the clinician to manage patients?

But an ideal biomarker of myocardial injury should possess more than that characteristics (*Figure 8*.).

Ideal characteristics of biomarkers
Present in high concentrations in the heart
Not preset in other tissues
Rapid release after cardiac injury
Persists in plasma
Allows the development of accurate and rapid assays
Allows the development of sensitive assays
Contributes to the diagnostic armamentarium

Figure 8. *Summary of the ideal characteristics of biomarkers [76].*

Actually none of the available tests for myocardial biomarkers meets all this criteria. No common biomarker is completely sensitive and specific for MI, especially in the acute phase within about 6h following the onset of chest pain. In this timeframe most emergency physicians have to make diagnostic and therapeutic decisions [77]. Timing and the correlation with patient symptoms, electrocardiograms and angiographic studies are very important [78].
Therefore, a multi-marker strategy has been reported to be useful in refining risk stratification among patients with acute coronary syndromes, and there is growing interest in this approach for categorising heart failure [79].
The following tests are available as markers for acute myocardial infarction:

Cardiac troponins, troponin I and T, are the current `gold standard´ for the detection of myocardial necrosis [80]. After MI troponin levels increase within 2 to 4h and persist for days in the blood *(Figure 9.*). Troponin I will remain elevated up to 5 to 10 days and troponin T up to 2 weeks [78].

Before the appearance of troponin assays, creatine kinase (CK) and its CK-MB fraction, which is specific for cardiac muscle were the `gold standards´ for diagnosing of MI. Increases in plasma levels usually occur 6-12h post MI, peaking at 24h, and returning to baseline after 36-72h *(Figure 9.)* [81].

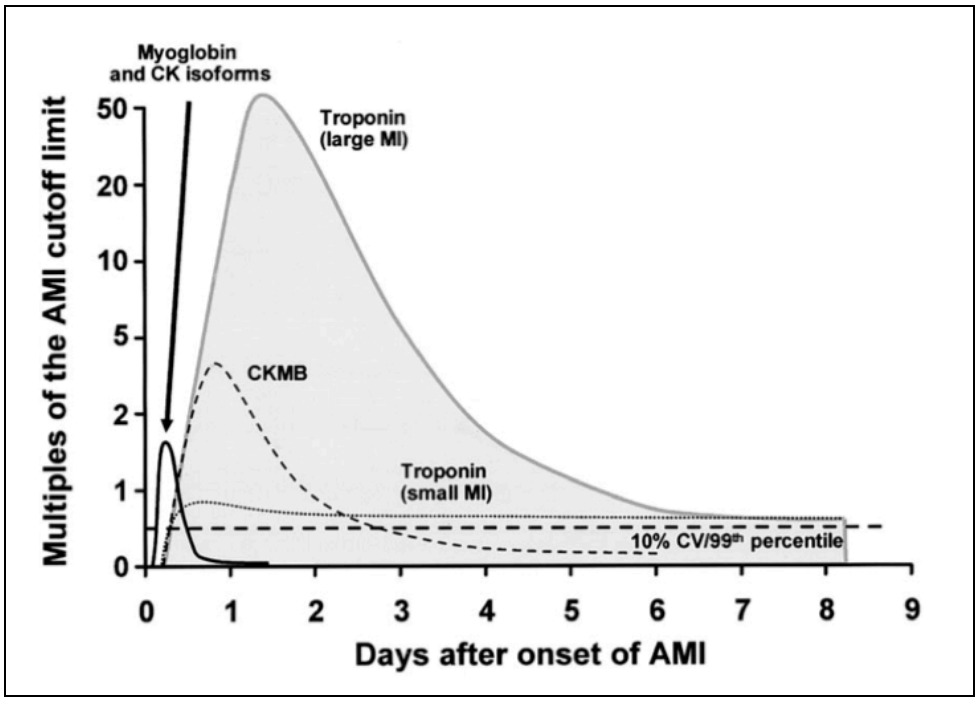

Figure 9. *Time course of various biomarkers in the blood after acute myocardial infarction (AMI). Shown are the time concentrations/activity curves for myoglobin, creatine kinase (CK) isoforms, troponin and CK-MB after large and small infarctions (CV = coefficient of variation) [78].*

Whereas troponins have become the most sensitive test to detect myocardial necrosis, B-type natriuretic peptide (BNP) and the amino terminal fragment of proBNP called NT-proBNP are increasingly recognised as the most sensitive test to detect cardiac stress and heart failure [80].

Additionally, myoglobin [81], lactate dehydrogenase (LDH) [82], C-reactive protein (CRP) [78], and serum glutamate oxaloacetate transaminase (SGOT) [76] can be useful to detect myocardial injury.

1.6. Tenascin-C in the Heart

1.6.1. Tenascin-C in Early Heart Development

TN-C is expressed during wound healing and remodelling processes in various tissues. Within the heart, TN-C is expressed only at the very early stage of organogenesis during embryonic development. In healthy adult myocardium only the chorda tendinae of papillary muscles is TN-C positive [83]. The remaining healthy heart is TN-C negative, but TN-C reappears in the myocardium under various pathological conditions, such as dilated cardiomyopathy, myocarditis, and myocardial infarction [84, 85].

In heart organogenesis, mesenchymal-epithelial transformation of the precardial mesoderm is an important step leading to differentiation of cardiomyocytes. A population of mesodermal cells elongate and differentiate to cardiomyocytes. This process requires extensive alteration of cell shape, arrangement of cells, and cell-cell interactions, which transmit important signals for differentiation of cardiomyocytes [86, 87].
TN-C is expressed in the epithelialising mesoderm, suggesting that the molecule could be involved in this dynamic cell activity.
Once cardiomyocytes become differentiated, they stop TN-C expression, with the exception of cells in the out-flow tract of the heart. It seems that cells of the out-flow tract are a special subpopulation of cardiomyocytes [88].

Imanaka-Yoshida et al. analysed TN-C and TN-X expression patterns in early cardiac development within wild-type and TN-C knockout mice [88]. This study demonstrated that TN-C is expressed at distinct time points and sites during early heart development in mice starting at E7.5. In contrast, TN-X is initially expressed at E11 as scattered small spots along the inter-ventricular groove, the AV groove, and over the surface of the atrium.
TN-C was transiently expressed by differentiating pre-cardiac mesodermal cells, cardiomyocytes in the looping out-flow tract, endocardial cells forming cushion tissues, and mesenchymal cells in the pro-epicardial organ (PEO), which are the

precursors of coronary vessels.
Despite restricted expression during cardiogenesis, the hearts of TN-C null mice developed normally [88].
The speculation that TN-X may compensate for the loss of TN-C cannot be approved. No difference in TN-X expression can be observed in TN-C null mice compared to wild-type mice and no TN-X was detected at sites where TN-C must be essentially expressed [88].

1.6.2. Tenascin-C in Myocardial Remodelling

Myocardial tissue remodelling plays an important role in progressing heart failure. In the healthy myocardium, myocytes are embedded in the ECM meshwork and a balance between MMP and TIMPs exist. An imbalance with increased MMP up-regulation is associated with ventricular dilatation and remodelling. Ventricular function can also be impaired by an abnormal increase in collagen synthesis, resulting in excessive fibrosis [79].

1.6.2.1. Tenascin-C in Post Myocardial Infarction Remodelling

The presence of TN-C and fibronectin in human myocardial tissue at different time points post MI (6h to 17 years) were analysed [67]. In the control group of healthy myocardium, fibronectin immunostaining was found in the subendothelial space in vessels. TN-C was completely absent in normal myocardium. While fibronectin was demonstrated in ischemic cardiomyocytes within 1 day, TN-C was found 4-6 days post infarction and was located at the margin of the area of infarction.
TN-C expression then shifted from the margin to the centre of infarction, where it could be found 2-3 weeks. More than 4 weeks after infarction, the scar tissue consisted of collagen fibres with sparse fibroblasts. By that time, both TN-C and fibronectin expression had disappeared.
Another interesting observation was the presence of TN-C, but not fibronectin, surrounding vacuolated glycogen-rich cells, or so-called hibernating cardiomyocytes [67].

In a rat model it was shown that within 24h after permanent coronary ligation, interstitial fibroblasts in the border zone between infarcted and non-infarcted myocardium, where extensive remodelling occurred, started to express TN-C mRNA [85]. TN-C loosens cardiomyocyte-matrix adhesion, which could help cell rearrangement. TN-C expression was down regulated on day 7 and was no longer apparent 14 days post MI. Three days post MI necrotic myocardial tissue began to be replaced by granulation tissue. Cardiomyocytes did not express TN-C, only fibroblasts at developing fronts and around necrotic cardiomyocytes were positive for TN-C.

These results suggest that TN-C, which is up-regulated during acute/early phase after MI in interstitial cells, has an important role in loosening strong adhesion to connective tissue and helping in the rearrangement of surviving cardiomyocytes.

The mechanisms how TN-C, which is generally thought to be a counter-adhesion molecule, can affect cell adhesion are quite complex.

In healthy myocardial tissue cardiomyocytes are firmly anchored to connective tissue with costamere complexes containing integrin, talin, vinculin, and laminin [85]. TN-C inhibits cardiomyocytes from forming those costameric contacts but increases the number of cells with non-costameric attachment [85].

TN-C may have a dual role in cardiac healing after MI. TN-C may loosen cardiomyocytes from the ECM, causing slippage of cardiomyocytes (*Figure 10.).* Deadhesion of cells through loss of actin fibers and focal adhesion plaques support cell migration and cell invasion of inflammatory cells post infarction [3].

In addition, TN-C up-regulates MMPs [89], promoting degradation and rearrangement of the ECM and loosen tissue, which leads to an increasing risk of wall thinning, cardiac dilatation, and rupture [90].

TN-C may also increase production of matrix components to strengthening the cardiac matrix. Increased production of ECM molecules, in contrast, may occur by TN-C mediated recruitment of myofibroblasts [85], which are the main cells involved in production of new collagen shortly after MI.

The elastic properties of TN-C, due to the stretch-induced unfolding of its FN-III domains, may also help to resist the increased mechanical loading to which the border zone of the infarct is subjected [42].

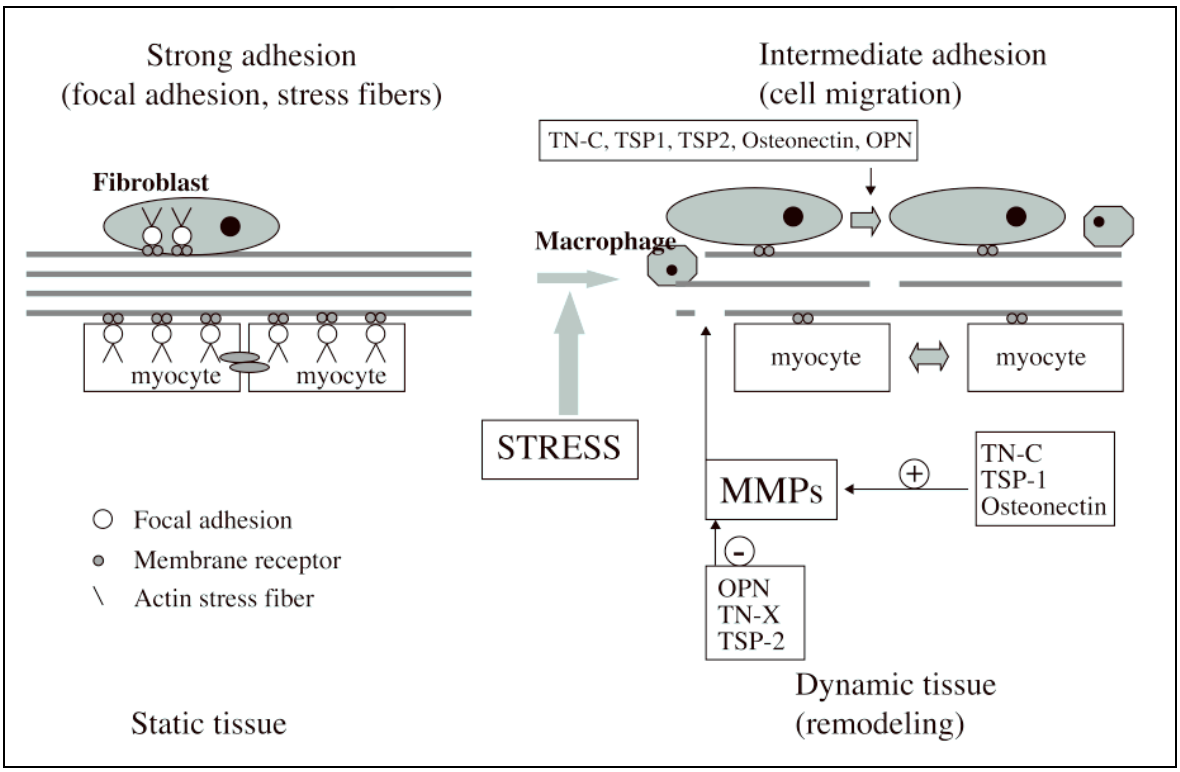

Figure 10. *A schematic diagram showing the possible role of matricellular proteins, including TN-C, during left ventricular remodelling of the heart [3].*

Whether TN-C reappearance after cardiac injury is beneficial or detrimental remains unclear, considering the paradoxical functions of TN-C in ECM remodelling. The precise role of TN-C in matrix remodelling after cardiac injury or stress requires further investigation in mice lacking the TN-C gene [3].

It was hypothesised that TN-C expression levels might be useful for the diagnosis and determination of left ventricular (LV) remodelling following myocardial infarction. Serum TN-C levels in patients with AMI and old myocardial infarction (OMI) were examined [91]. In the AMI group TN-C was significantly increased and peaked at day 5, then gradually decreased, although remained elevated at day 28.

TN-C levels were significantly higher in the LV remodelling group than in the non-remodelling group. AMI patients with high TN-C levels were at much higher risk of major adverse cardiac events (MACE) for up to 5.5 years [91].

Thus, serum TN-C levels in acute stages following infarction might be a predictive biomarker of LV remodelling during the recovery phase and prognosis.

In a myocardial wound healing model TN-C knockout mice were compared to wild-type mice after electrical injury to the myocardium [92, 93]. In knockout mice, myocardial repair seemed to proceed normally, but the appearance of myofibroblasts was delayed. These results indicate that TN-C is an important key player by stimulating cell migration and differentiation and promote recruitment of myofibroblasts in the early phase of myocardial repair [92].

1.6.2.2. Tenascin-C in the Heart Failing Process

In biopsy specimens from patients with acute myocarditis the degree of TN-C expression correlates with the severity of histological lesions - maybe TN-C reflects disease activity in cases of human myocarditis [94].
Furthermore, TN-C expression correlates with cardiac injury and inflammation, and the TN-C expression level has been proposed as a marker for the severity of viral myocarditis [84].

Imanaka-Yoshida et al. analysed TN-C expression in a myosin-induced autoimmune myocarditis mouse model [84]. TN-C expression was up-regulated at a very early stage of myocarditis (at day 14-16). During the active phase of myocarditis (about day 45), two isoforms of TN-C at 210kD and 250kD were identified in mouse myocardium, while only a faint band of the smaller isoform with 210kD was detected in the normal myocardium. TN-C immunostaining was always observed at the periphery of necrotic or degenerating cardiomyocytes in foci of inflammation. The expression level correlated with histological evidence of inflammatory activity [84].

Especially fibroblasts have a crucial role in regulating ECM remodelling, Frangogiannis et al. analysed the phenotypic characteristics of interstitial fibroblasts [95]. Expression of smooth muscle myosin heavy chain and TN-C was analysed, in the interstitium of hibernating human myocardium to examine the relation to recovery of myocardial function after revascularisation [95].
They demonstrated persistent interstitial deposition of TN-C in the dysfunctional human myocardium, which suggests an active process of ECM remodelling. The TN-C:collagen ratio, a marker of TN deposition in the cardiac interstitium, was

significantly higher in segments with recovery, suggesting the presence of an active remodelling process in hibernating segments. These findings support the concept that ischemic cardiomyopathy represents a dynamic process associated with continuous deposition of ECM. Resulting to a state of extensive fibrosis potentially associated with a lower chance of functional recovery [95].

Sato et al. analysed TN-C up-regulation in chordae tendineae of the anterior cusp of the left ventricular papillary muscle with aging [83]. TN-C distribution was studied in both, a 20s age group and an 80s-90s age group. Interestingly, concentrations of TN-C increased in response to mechanical stress and aging.

TN-C level was analysed by immunochemistry in biopsy specimens of hearts obtained from patients with idiopathic dilated cardiomyopathy (IDC) [96]. IDC is a disorder of unknown aetiology characterised by left ventricular cavity enlargement and wall thinning, in association with reduced left ventricular wall motion. In IDC specimens TN-C was distributed in the enlarged perimysium and endomysium near replacement fibrotic lesions close to necrotising myocytes and in the peripheral portion of the replacement fibrotic lesions. Concluding that TN-C plays an important role in the initiation of replacement fibrosis in patients with IDC.
Furthermore, circulating serum TN-C level was analysed in a small population of 31 cases in patients with IDC and demonstrated that serum TN-C is up-regulated after IDC [97]. Also a positive correlation between circulating TN-C and BNP levels, which is an indicator for cardiac insufficiency, had been demonstrated. Patients with detectable cardiac troponin T, a marker of ongoing myocardial damage in chronic heart failure, had higher TN-C levels than those without it. Circulating levels of TN-C were positively correlated with those of pro-collagen type III amino-terminal peptide, a marker of cardiac fibrosis synthesis in myocardial infarction and chronic heart failure. Suggesting, that increased levels of circulating TN-C indicate ongoing replacement fibrosis after a loss of cardiomyocytes in IDC [97].
These results confirm the histopathologic observations of Tamura et al. [96], who showed that TN-C is specifically localised along the margin of fibrotic areas.
Terasaki et al. confirmed preliminary results obtained from this small study population with a larger dilated cardiomyopathy (DCM) population (n = 107) and showed a clearer association between higher TN-C levels and LV remodelling, as well as LV

dysfunction. Serum TN-C levels were analysed by enzyme-linked immunosorbent assays (ELISA) and demonstrated that increased serum TN-C levels indicate the severity of heart failure, left ventricular dysfunction and remodelling in patients with DCM [98].

1.7. Medical Applications of Tenascin-C

Besides the extensive use of TN-C antibodies in immunohistochemistry, the use of TN-C antibodies has been also expanded to in vivo studies. In the case of TN-C, antibodies have been used for oncological diagnosis and therapies [35]. It was found that TN-C expression is correlated with angiogenesis and local infiltration of normal tissue by tumour cells of various types of carcinomas [99].
Even targeting human antibodies specific to alternatively spliced domains of the large TN-C isoform are promising building blocks for the development of antibody-based pharmaceuticals [100].
In a phase-II trial ^{131}I-labeled monoclonal antibodies to human TN-C have yielded promising results when used as radio-immunotherapy for patients with newly diagnosed malignant gliomas [101]. These treatments have been pioneered in patients with brain tumours [102, 103]. Since TN-C is weakly expressed in normal adult brain, but strongly expressed in those tumours, this radiolabeled tool allows selective destruction of tumour cells. The antibody anchors the radioisotope direct at the tumour tissue side, which is rich in TN-C and thus provide for local radiation.
Yet another promising development is the isolation of size-minimised and nuclease-stabilised TN-C aptamers, which can be considered as oligonucleotide analogous of antibodies. Aptamers exhibit high affinity and specificity for their cognate proteins. They may be beneficial for tumour targeting due their smaller size than antibodies, and could be used for targeted delivery of radioisotopes [104].

A number of studies have investigated TN-C levels in body fluids, such as synovial fluid of patients with rheumatoid arthritis in order to assess the possibility of using TN-C as a marker of specific diseases [105]. Increased serum TN-C levels are in conjunction with neoplasia and inflammation, including inflammatory bowel disease (IBD) [106] and chronic hepatitis C (CHC) [107]. Elevated TN-C serum levels were

observed, as mentioned before, in pathologies such as myocardial infarction [91] and IDC [97]. TN-C levels in patients with dilated cardiomyopathy showed a significantly positive correlation with NYHA (New York Heart Association) functional class [98].
Furthermore in patients with IDC, levels were negatively correlated with the left ventricular ejection fraction, positively correlated with left ventricular end-systolic diameter and BNP level. Additionally, levels of circulating TN-C were higher in patients with detectable cardiac troponin T than in those without [97].

Another, indirect way of therapeutic strategy may be the determined regulation of MMPs, which play an important role in degrading TN-C. Regulation of myocardial MMP expression and activity may be important for controlling myocardial matrix remodelling in the developing of heart failure [108].
Mouse models have been created with mutations in the MMP/TIMP genotype and will likely act as a major tool for further analyses [108]. Determination between different TN-C isoforms, knowledge of shift in isoform expression and potential interaction partner will be subject of further studies to understand the complex function of this protein.
Nevertheless, the broad distribution of tissues capable of synthesising TN-C, and its induction under so many pathological conditions, suggest that TN-C presence in serum is not sufficiently specific to be useful in diagnosis. But measurement of TN-C levels may, however, be useful in assessing prognosis and response to treatment [91, 98, 106, 107].

Aim of the thesis

In contrast to small TN-C isoforms, which are up-regulated in healthy ECM, large TN-C isoforms are up-regulated under pathologic conditions [44].
Whereas the healthy, adult heart is TN-C negative, TN-C protein is detectable in injured cardiac tissue after myocardial infarction (MI) [85].
This protein up-regulation and shift in isoform expression in the myocardial healing process demonstrates a potent mechanism to influence cell-cell and cell-ECM interactions [44].

The aim of this thesis was to show a detailed time-dependent expression pattern of the matricellular protein TN-C in the early remodelling process post MI (12 hours to 14 days). Furthermore, the complete rat TN-C cDNA sequence was analysed and the up-regulation of four specific TN-C isoforms in left ventricular remodelling after myocardial infarction were demonstrated.

2. MATERIAL AND METHODS

2.1. Animal Model of Myocardial Infarction

Male Sprague-Dawley rats (Core Unit for Biomedical Research, MUW, Himberg, Austria) weighting 300 ± 50g were used in the study.
All animals had free access to standard rat chow and fluid during the observation period and received human care in compliance with the European Convention on Animal Care and the local animal research advisory board.

Myocardial infarction was induced by ligation of the left anterior descending coronary artery (LAD) according to the technique of Pfeffer et al. [109] as described recently [110, 111]: initially, rats were anaesthetised intraperitoneally with a mixture of xylazine (1mg/100g bodyweight, i.p.; Rompun®, Bayer Health Care, Vienna, Austria) and ketamine (10mg/100g bodyweight, i.p.; Ketasol®, Graeub Veterinary Products, Senden-Bösensell, Germany). Rats were shaved on their left side between the axilla and the costal arch and placed on the operation table. Rats were intubated with a fine polyethylene tube and ventilated mechanically by a rodent ventilator using oxygen and room air (60 min-1). 0.2% isofluran (Forane®, Abbott, Kent, United Kingdom) was added to the oxygen-air mixture.
Subsequently, the skin was incised over the 4th intercostal space. The underlying musculature was blunt dissected in order to reveal the intercostal musculature. The chest was entered via left thoracotomy in the fourth intercostal space, and a pair of retractors was used to open up the cavity.
After removing the pericardium, the beating heart and the LAD was visualised and a 6-0 prolene* ligature (Ethicon, Edinburgh, United Kingdom) was placed around the LAD (*Figure 11*.) beneath the left auricle.
After coronary ligation and 1h post surgery lidocaine (1mg/100g bodyweight, i.m.; Xylanaest purum 2%, Gebro Pharma, Fieberbrunn, Austria) was applied.

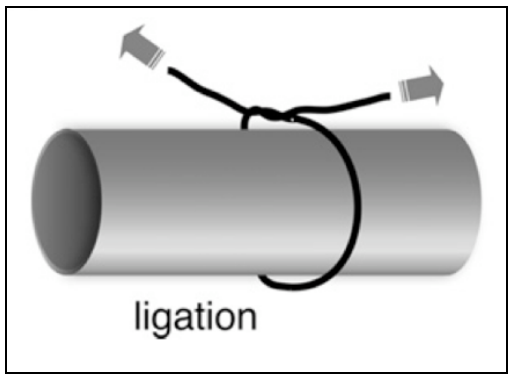

Figure 11. *Model of ligation [112].*

Immediately after confirming the efficacy of the ligation (wanly coloration of the anterior wall of the ventricle) the chest was closed after being evacuated by a small polyethylene cannula and isofluran supply was stopped.
Sham operated rats underwent the same procedure, except the ligature around the LAD.
After myocardial infarction the perioperative mortality in the first 48h was about 25%.
During the follow-up period no animal died.
The skin was sutured with a 3.0 vicryl* plus suture (Ethicon, Edinburgh, United Kingdom). Immediately after awakening, the rats were placed back into their cage. Three hours after surgery a subcutaneous analgetic injection of Piritramid (0.01ml/100g bodyweight; Dipidolor®, Janssen-Cilag Pharma, Vienna, Austria) was applied.

For studying TN-C expression levels eight different time points post MI were selected: 0.5, 1, 2, 3, 5, 7, 10, 14 days post MI, and compared to a sham operated control group (*Table 1.*). In this study only animals with a myocardial infarction of ≥ 20% of the left ventricle were included.

Days post MI	Group size (total)	Group size (MI ≥ 20%)
0.5	16	4
1	16	6
2	16	7
3	16	7
5	16	6
7	16	5
10	16	5
14	16	6
Sham control	10	10
Reserve	40	-
Total	**178**	**56**

Table 1. *Study design (MI = myocardial infarction).*

2.2. Sample Preparation

After 0.5 to 14 days of survival the rats were sacrificed. Hearts were excised quickly and put into ice-cold saline. To analyse free wall and scar tissue within cross sections hearts were cut mid-papillary (*Figure 12.).* The upper part was used for histological analysis and fixed in 7.5% paraformaldehyde (SAV Liquid Production, Flintsbach, Germany) at 4°C. After fixation tissue samples were embedded in paraffin (Paraplast Plus*; McCormick Scientific, St. Louis, USA) and cut into 5μm slices.

In contrast, the lower, apical part of the heart was used for isolation of RNA and proteins. Therefore, samples were collected from scar tissue and the non-infracted free wall area of the LV. Specimens were shock-frozen using liquid nitrogen immediately after harvesting and stored at -80°C.

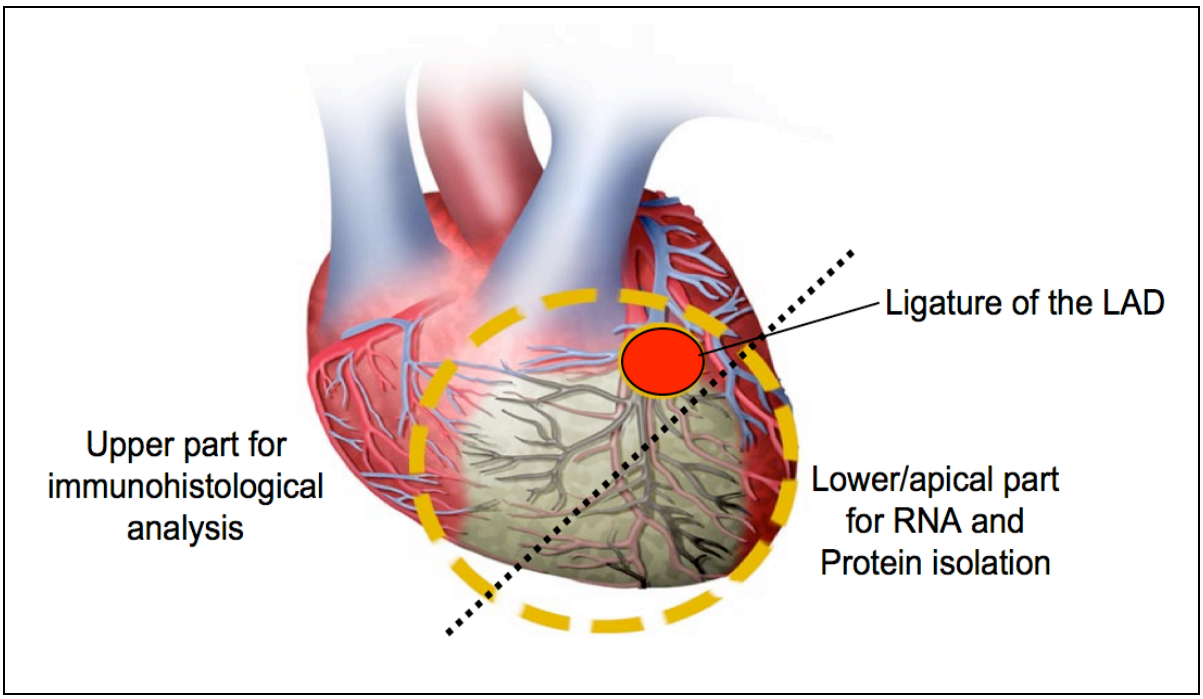

Figure 12. *Schematic diagram of sample preparation. Hearts were cut mid-papillary (indicated by the dotted line; LAD = left anterior descending coronary artery*) [113].

2.3. RNA Isolation

For RNA isolation 1ml TRI-reagent (Sigma, Steinheim, Germany) was used to homogenise 50-100mg cardiac tissue. Samples were incubated 5min at RT before 0.1ml BCP/ml TRI-reagent was added (1-bromo-3-chloro-propane; Sigma, Steinheim, Germany). Samples were mixed well, incubated 2-15min at RT and centrifuged for 15min at 4°C at 12.000xg.

Following centrifugation, the mixture was separated into a lower red phenol-chloroform phase, an interphase, and a colourless upper aqueous phase. RNA remains exclusively within the aqueous phase.

The aqueous phase was transferred to a fresh tube, and the organic phase was saved for protein isolation. From the aqueous phase RNA was precipitated.

Samples were mixed with 0.5ml isopropyl alcohol/ml of TRI-reagent (Sigma, Steinheim, Germany), incubated 5-10min at RT and centrifuged at 12.000xg for 8min at 4°C. RNA precipitate was visible as a small white pellet on the side and bottom of the tube. Supernatant was removed and the RNA pellet was washed two times with

75% ethanol (Merck, Darmstadt, Germany) and centrifuged at 7.500xg for 5min at 4°C.
Finally the RNA pellet was briefly air-dried and dissolved in RNase-free H_2O. RNA was quantified by spectrophotometric measurement of the absorbance at 260/280nm and RNA samples were stored at -80°C until further processing.

2.4. Protein Isolation

Proteins were precipitated from the phenol-ethanol supernatant (approximate 0.8ml/ml of TRI-reagent). Furthermore 1.5ml isopropyl alcohol/ml of TRI-reagent was added for initial homogenisation. Samples were incubated for 10min at RT and protein precipitates were sedimented at 12.000xg for 10min at 4°C. Supernatant was removed and the protein pellet was washed 3 times in 1.8ml wash solution containing 0.3M guanidine hydrochloride (Sigma, Steinheim, Germany) dissolved in 95% ethanol. During each wash cycle, the protein pellet was stored in the wash solution for 20min at RT and centrifuged at 7.500xg for 5min at 4°C. After the third wash step protein the pellet was washed 2 times in ethanol and centrifuged at 7.500xg for 5min at 4°C. Supernatant was removed and protein pellet was air-dried for 5-10min. Pellet was dissolved in 1% sodium dodecyl sulfate (SDS; Sigma, Vienna, Austria) by pipetting up and down.
Bradford protein assay (Bio-Rad Laboratories, Munich, Germany) was used to measure spectrometrical the protein concentration of all samples according to the manufacturer's instructions,
Samples were stored at -20°C for future use.

2.5. cDNA Synthesis

For cDNA synthesis 2.5µg sample were used with either 0.5µg oligo $(dT)_{18}$ or specific TN-C primer (Tnc-3_rev, Tnc-8_rev, Tnc-14_rev, and Tnc-18_rev; see *Table 3*.; VBC, Vienna, Austria). All primers were designed according to mouse (GenBank, NM_011607) and human (GenBank, NM_002160.1) mRNA TN-C sequence. To

reach the total volume of 14µl, ddH_2O was added. Samples were incubated at 70°C for 5min and chilled on ice. After adding of 4µl 5x reaction buffer (250mM Tris-HCl, pH 8.3 at 25°C, 250mM KCl, 20mM MgCl, 50mM DTT) and dNTP mix (500µM/dNTP) samples were incubated at 42°C for 5min (Fermentas, Vilnius, Lithuania).
For the first strand synthesis 1µl Superscript II Enzyme (Affymetrix, High Wycombe, United Kingdom) was added and incubated for 1h at 42°C. Reaction was terminated at 70°C for 10min followed by cooling down on ice.

2.6. PCR

To get a total volume of 25µl, 2µl sample, 2.5µl primermix with forward and reverse primer (25µM/primer; VBC, Vienna, Austria), 0.5µl dNTPs (10mM), 1µl dimethyl sulfoxide (DMSO), 2.5µl 10x buffer+$MgCl_2$ and 0.2µl long PCR enzyme mix (5u/µl) were mixed (Fermentas, Vilnius, Lithuania).
In *Table 2*. TN-C and GAPDH PCR protocols are summarised and in *Table 3.* all PCR and sequencing primers, designed by using Primer 3 Software (http: //frodo.wi.mit.edu/), were listed.

	TN-C			GAPDH		
Step	**Temperature**	**Time**	**Cycles**	**Temperature**	**Time**	**Cycles**
1.	95°C	Pause		94°C	5min	
2.	96°C	5min		94°C	1min	
3.	95°C	40sec		56°C	1min	
4.	60°C	1min		72°C	1min	x39
5.	72°C	3min	x39	72°C	10min	
6.	72°C	5min		15°C	Pause	
7.	15°C	Pause				

Table 2. *Protocols for TN-C and control GAPDH PCR.*

Primer	Sequence (5´-3´)	Length (bp)
Tnc-1_for	GCCAGCCATTGCCACTGT	18
Tnc-2_for	AAAATGCAGCCACAGTCAGC	20
Tnc-3_rev	GCCCATCAAATGCCCAAG	18
Tnc-4_rev	CGCCTGCCTTCAAGATTTC	19
Tnc-5_rev	CGCCTGCCTTCCAGATTTC	19
Tnc-6_rev	CGCCTGCCTTCMAGATTTC	19
Tnc-7_for	ACAGTGGATGGGGAAAACCA	20
Tnc-8_rev	AATCCCTTCATGGCAATCACACT	23
Tnc-9_for	CGAAGGTGGGGTCCTCAAGA	20
Tnc-10_for	AGGTGAAAGATGTCACAGACACCA	24
Tnc-11_for	CAAGCCACAACCAAAACCACA	21
Tnc-12_rev	TGCTTTTTGGTATCTCTGATCCTG	24
Tnc-13_for	TGTAATCTCAGAGGCCAGTGC	21
Tnc-14_rev	GTGTGGGGCTCAGGTCTTTC	20
Tnc-15_for	GCTCAGTGGATCTAGAGTCAACGA	24
Tnc-16_rev	TCGTTGACTCTAGATCCACTGAGC	24
Tnc-17_for	ACCGGAGAAGACTGTAGCCAAC	22
Tnc-18_rev	AGTCTGGGTCATGTCAGCCTCTA	23
Tnc-19_for	ATGAGATGCGGGTCACTGAGTA	22
Tnc-20_rev	GTAAGTCCCTGGGTGCATCAAT	22
Tnc-21_for	TTCTTYCAAGAAGATYRGGGACA	23
Tnc-22_for	GTACCCTASAGMYCTAGAG	20
Tnc-23_for	GAGCCAGGGCAAGAATACAC	20
Tnc-24_rev	GTAATAGCGGGTGGCTGCT	19
Tnc-25_for	AGAGACACCTAGCCAATCCAA	21

Tnc-26_rev	GTTTTCTCTGGGCCCCATT	19
Tnc_for_m+r	GCATCCGTACCAAAACCATCAGTA	24
Tnc_rev_m+h+r	CAGTGGCCTCTCTGAGACCTGTTA	24
GAPDH_for	CCATCACCATCTTCCAGGAGC	21
GAPDH_rev	GGCAGTGATGGCATGGACTG	20

Table 3. *Summary of TN-C and GAPDH primer used for PCR analysis and sequencing.*

2.7. Sequencing

All sequences were obtained from purified or pure PCR products (4base Lab, Reutlingen, Germany). To purify PCR samples, probes were run on a 1% agarose gel (UltraPure™ Agarose; Invitrogen, Carlsbad, USA). Gel bands were cut out of the gel and purified by using GFX™ PCR DNA and gel band purification kit (GE Healthcare, Freiburg, Germany). Samples were analysed, and different isoforms were identified by using Codon Code Aligner Software (Version 2.0.2.; CodonCode Corporation, Dedham, USA).

2.8. Real Time-PCR

Real-time PCR was performed by using LightCycler-RNA Master SYBR Green I for GAPDH protein and Universal Probe Library for TN-C (*Table 4*.), according to the manufacturer's instructions (Roche Applied Science, Mannheim, Germany). Primers (*Table 5*.) were designed using Primer 3 Software (http: //frodo.wi.mit.edu/).
Amplification conditions included an initial incubation at 61°C for 20min, followed by incubation at 95°C for 30sec and 50 cycles of 95°C for 1sec. The respective annealing temperature was 63°C for TN-C and 65°C for GAPDH for 10sec and 72°C for 10sec, followed by a melting step from 45°C to 95°C, increasing 0.1°C/sec and a final cooling to 40°C. Finally data were analysed by using LightCycler Software

(Version 3.5; Roche Applied Science, Mannheim, Germany).
Primer efficiency was 1.90 for TN-C and 1.85 for GAPDH primer.

TN-C	
H_2O	10µl
UPL Probe #71 (1:5)	1µl
Primer rev (25pmol/µl)	1µl
Primer for (25pmol/µl)	1µl
Red Cap 1	4µl
Probe	3µl
Total	**20µl**

GAPDH	
H_2O (Nr. 3)	7.2µl
White Cap (Nr. 2)	1.3µl
Primer rev (10pmol/µl)	1µl
Primer for (10pmol/µl)	1µl
Red Cap	7.5µl
Probe	2µl
Total	**20µl**

Table 4. *Diagram of TN-C and GAPDH real time-PCR mix.*

Primer	Sequence (5´-3´)	Length (bp)	Fragment size (bp)
Tnc_for	AGGGTTTCACTGGGGAAGA	19	60
Tnc_rev	CCTGGTCATTGCAGTCATTG	20	
GAPDH_for	ACAGTCCATGCCATCACTGCC	21	265
GAPDH_rev	GCCTGCTTCACCACCTTCTTG	21	

Table 5. *Summary of TN-C and GAPDH primer used for real time-PCR analysis.*

2.9. Histological and Immunohistochemical Analysis

2.9.1. H&E Staining and Infarct Size Measurement

Before staining, slices were deparaffinised in xylene and dehydrated through a graded ethanol series (100%, 96%, 2x80% and 2x70% EtOH).
H&E stained slices (Mayers Haematoxylin; Sigma, Steinheim, Germany and eosin; Merck, Darmstadt, Germany) were covered with Eukitt (O. Kindler GmbH, Freiburg, Germany).
For infarct size measurement slides were scanned with highest magnification (3200dpi) and analysed blinded by two investigators. Using Image J Software (ImageJ 1.38w; http://rsbweb.nih.gov/ij/) the inner and outer outline of the left ventricle including the septum was measured and percentages of scar tissue was analysed. Additionally, cross section dimension of scar and free wall tissue of the left ventricle and septum were measured.

2.9.2. Trichrome (Goldner) Staining

After slices were deparaffinised in xylene and dehydrated through a graded ethanol series (100%, 96%, 2x80% and 2x70% EtOH), slices were incubated with haematoxylin for 8min, rinsed with dH_2O for 10min and stained 5min with fuchsin acid-Ponceau (0.2g Ponceau S, 0.1g fuchsin acid in 300ml dH_2O and 0.6ml acetic acid; Merck, Darmstadt, Germany). Slices were washed in 1% acetic acid (VWR, Briare, France) and incubated with phosphotungstic acid-Orange G (4g phosphotungstic acid and 2g Orange G in 100ml dH_2O; Merck, Darmstadt, Germany) for 5min.
Slices were washed again in 1% acetic acid and incubated with 1% light green solution (SF yellowish; Merck, Darmstadt, Germany) in 2% acetic acid for 6min. Finally, samples were washed and rehydrated in 80% and 100% EtOH, fixed in xylene and covered in Eukitt (O. Kindler GmbH, Freiburg, Germany).

2.9.3. TN-C Staining

All sides used for IHC staining were coated with 1% poly-L-lysine (Sigma, Steinheim, Germany) for 15min and dried over night at 37°C.

Before staining, slices were deparaffinised in xylene (Fisher Scientific, Leicestershire, United Kingdom) and dehydrated through a graded ethanol series (100%, 96%, 2x80% and 2x70% EtOH).
All slices were pretreated with 0.1% pepsin solution (Boehringer-Mannheim, Mannheim, Germany) in 0.01N HCL (pH 2.3; Sigma-Aldrich, Steinheim, Germany), for 7min at RT to retrieve the antigens. After three 10min washes in PBS, slices were incubated with horse blocking serum (Vectastain Elite ABC Kit, Vector Laboratories, Vienna, Austria) for 20min at RT. Slices were washed again three times and incubated overnight with primary monoclonal mouse antibody, α-human TN-C (1:10, IgG1, Clone 4F10TT; IBL, Hamburg, Germany) at 4°C in a wet camber. After overnight incubation slices were washed three times for 10min in PBS followed by incubation with secondary horse α-mouse-Bio antibody (3:200; Vector Laboratories, Burlingame, USA) for 30min at RT. Slices were washed another three times with PBS for 10min and incubated with ABC-Reagent (1:50; Vector Laboratories, Vienna, Austria) according to the manufacturer's instructions for 30min at room temperature.
After sections were washed three times for 10min in PBS, sections were incubated with diaminobenzidine (DAB) substrate Kit (Vector Laboratories, Burlingame, USA) for 10min to visualise positive immunoreactions. Slices were washed in dH_2O, weakly counterstained with haematoxylin solution (Sigma, Steinheim, Germany) washed three times with H_2O and covered in mounting medium (Dako, California, USA).

20x PBS (pH 7.4): 1 liter

2.74M NaCl (Sigma, Steinheim, Germany)
54mM KCl (Sigma, St. Louis, USA)
86mM Na_2HPO_4 (Merck, Darmstadt, Germany)
28mM KH_2PO_4 (Sigma, Steinheim, Germany)

1x PBS (pH 7.4): 1 liter

50ml 20x PBS

950ml H_2O

2.10. Polyacrylamide Gel Electrophoresis and Western Blot Analysis

Protean II (Bio-Rad Laboratories, Munich, Germany) equipment was used to cast two 0.75mm thick gels. The resolving gel was poured in two phases: the first (bottom) phase was a plain of 7% polyacrylamide gel. For 2 gels: 3.5ml acrylamide (Serva, Heidelberg, Germany), 3.75ml 1.5M tris (pH 8.8; Sigma, Steinheim, Germany), 7.6ml ddH_2O, 100µl 10% Ammonium persulfate (APS; Sigma, Steinheim, Germany), 75µl 20% SDS (sodium dodecyl sulfate; Sigma, Steinheim, Germany), and 10µl TEMED (tetramethylethylenediamine; Promega, Madison, USA) were used.
The upper stacking gel contained 625µl acrylamide, 925µl 0.5M tris (pH 6.8), 2.125ml ddH_2O, 50µl 10% APS, 18.75µl 20% SDS, and 2.5µl TEMED.

2.10.1. Sample Preparation

Protein samples were slowly thawing on ice and diluted 1:1 with *Laemmli* sample buffer. Samples were boiled at 95°C for 10min and slowly cooled down on ice.
15µg protein sample were subjected to 7% SDS-PAGE. Gels run at 40V for about 1h and 60V for ~2h. Purified human TN-C protein (2ng) was used as positive control and for standardisation (Millipore, Vienna, Austria).

After electrophoresis proteins were blotted with 0.04mA over night at 4°C onto a PVDF (Polyvinylidenfluorid) membrane (0.45µm; Millipore, Bedford, USA). Before the transfer started the membrane was incubated with pure methanol (Fisher Scientific, Leicestershire, United Kingdom) for a few seconds, 7½min in ddH_2O and 7½min in transfer buffer. Thereafter, blotting efficiency was checked by Coomassie gel staining (Coomassie brilliant blue R-250; Sigma, Steinheim, Germany). Gels were incubated 15min in staining solution followed by incubation in Coomassie destaining solution to visualise proteins left in the gel.

Unspecific binding sites on the membrane were blocked by incubation with blocking solution (5% low-fat dried milk powder in TBS-T; Fixmilch-Instant, Maresi, Vienna, Austria) on a rocking table for 1h at room temperature followed by three 10min washes with TBS-T.

All blots were incubated with primary monoclonal mouse α-human TN-C antibody (1:100, IgG1, Clone 4F10TT; IBL, Hamburg, Germany) over night at 4°C on a rocking table. This antibody specifically recognised the EGF-L domains of all TN-C variants. After incubation the blots were washed 3 times for 10min in TBS-T.

For detection blots were incubated with secondary goat α-mouse horseradish peroxidase (HRP) antibody (1:10.000; Dako, Glostrup, Denmark) in blocking solution for 1h at room temperature.

After three 10min washes with TBS-T each membrane was incubated with 2ml freshly prepared enhanced-chemiluminescence (ECL) solution and 50µl H_2O_2 (GE Healthcare, Buckinghamshire, United Kingdom) in the dark room. Membranes were covered in a plastic foil and signals of immunoreactive bands were visualised by exposure of ECL films (GE Healthcare, Buckinghamshire, United Kingdom) for 10sec, 30sec, 1min, 5min and 10min.

For standardisation same membranes were washed for 1h with TBS-T, blocked again with blocking solution and incubated with β-actin antibody (1:2.000, clone AC-15; Sigma, Steinheim, Germany) for 1h at room temperature. After three washing steps, membranes were incubated with secondary goat α-mouse HRP antibody (1:10.000; Dako, Glostrup, Denmark) in blocking solution for 1h at room temperature. Following the last washing step specific signals were displayed as mentioned before.

Western blots were analysed using ImageMaster® 1D Software (Version 2.01; GE Healthcare, Freiburg, Germany). Quantity calibration was made using 2ng purified human TN-C (Chemicon/Millipore, Vienna, Austria) as standard. Amount of both TN-C isoforms, the large and the small, was calculated separately in comparison with the standard curve of known value.

2.10.2. Buffers and Solutions

10x running buffer: 1 liter

Tris: 30.3g (Sigma, Steinheim, Germany)

Glycine: 142.6g (Sigma, Steinheim, Germany)

SDS: 10g

10x transfer buffer: 1 liter

Tris: 30.3g

Glycine: 142.6g

1x transfer buffer: 500ml (always fresh prepared before use)

10x transfer buffer: 50ml

ddH_2O: 350ml

Methanol: 100ml

20x TBS-T: 1 liter

Tris: 48.4g

NaCl: 160g (Sigma, Steinheim, Germany)

Tween 20: 20ml (Sigma, Steinheim, Germany)

37% HCL: 22ml

10x TBS (pH 8.0):

Tris: 12.1g

NaCl: 87.7g

2x Laemmli sample buffer:

125mM Tris (pH 6.8)

4% SDS

10% β-Mercaptoethanol (Merck, Darmstadt, Germany)

0.002% Bromphenol blue (Merck, Darmstadt, Germany)

20% Glycerine

Coomassie brilliant blue:

0.1% Coomassie brilliant blue R-250 in destaining solution (store at RT)

Coomassie destaining solution:

Methanol: 80ml

Acetic acid: 20ml (Merck, Darmstadt, Germany)

H_2O: 100ml

2.11. Statistical Analysis

All data within the text, figures, and tables were shown as means ± standard deviation (SD). For analysis of data Microsoft Excel for Mac was used. Statistical analysis was performed using GraphPad Prism software (Prism 4, version 4.0c for Mac, GraphPad Software, San Diego California USA, www.graphpad.com). Significant results were specified using one-way ANOVA with corresponding post hoc test. Dunnett´s post hoc test was selected to compare infarction groups to the control group. Tukey test was used to compare all groups.

Statistical significance was achieved at a probability value of $*p < 0.05$.

3. RESULTS

3.1. Sequencing Results

Until now the sequence of the rat TN-C gene was unknown. Only a small fragment with about 1.856bp was published [114]. By using a total of 28 oligonucleotide TN-C primers (*Table 3.* and *Figure 13.)* the contiguous rat TN-C transcript was sequenced. This sequence (see *Appendix*) encompassing an open reading frame of 6.057bp that encodes 2.019 amino acids with a calculated molecular weight of 222kDa [115].

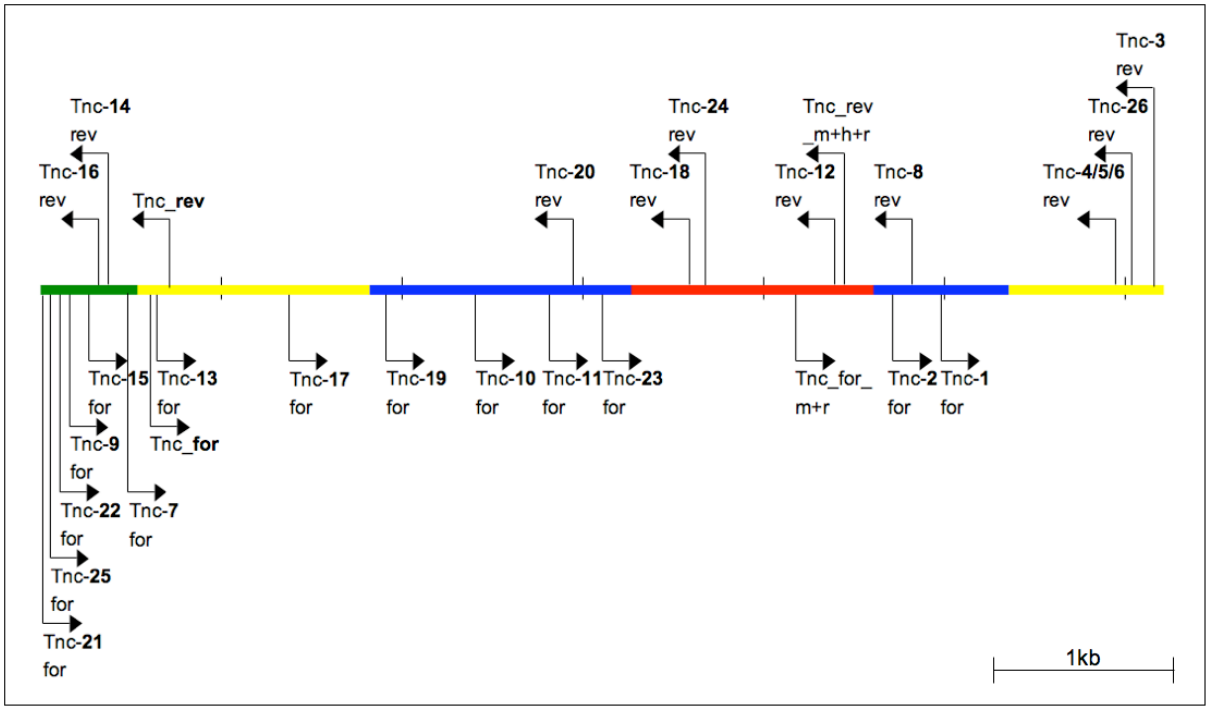

Figure 13. *Schematic diagram of primers used for sequencing the complete rat TN-C cDNA (primer: Tnc-1_for to Tnc-26_rev, Tnc_rev_m+h+r and Tnc_for_m+r) and real time-PCR analysis (primer: Tnc_for and Tnc_rev; shown in direction from left to right: in green = tenascin assembly domain, yellow = epidermal growth factor like repeats, blue = constant fibronectin type III domains, red = alternative spliced fibronectin type III domains, yellow = fibrinogen globe).*

The largest TN-C isoform, which was identified after MI, contained 5 FN-III domains in the alternative spliced region, called domain A1, A2, A4, B, and D (*Figure 14.).* Those 5 domains have a common size of 1.36kb. *Figure 14.* demonstrates primer used for sequencing the complete FN-III domains.

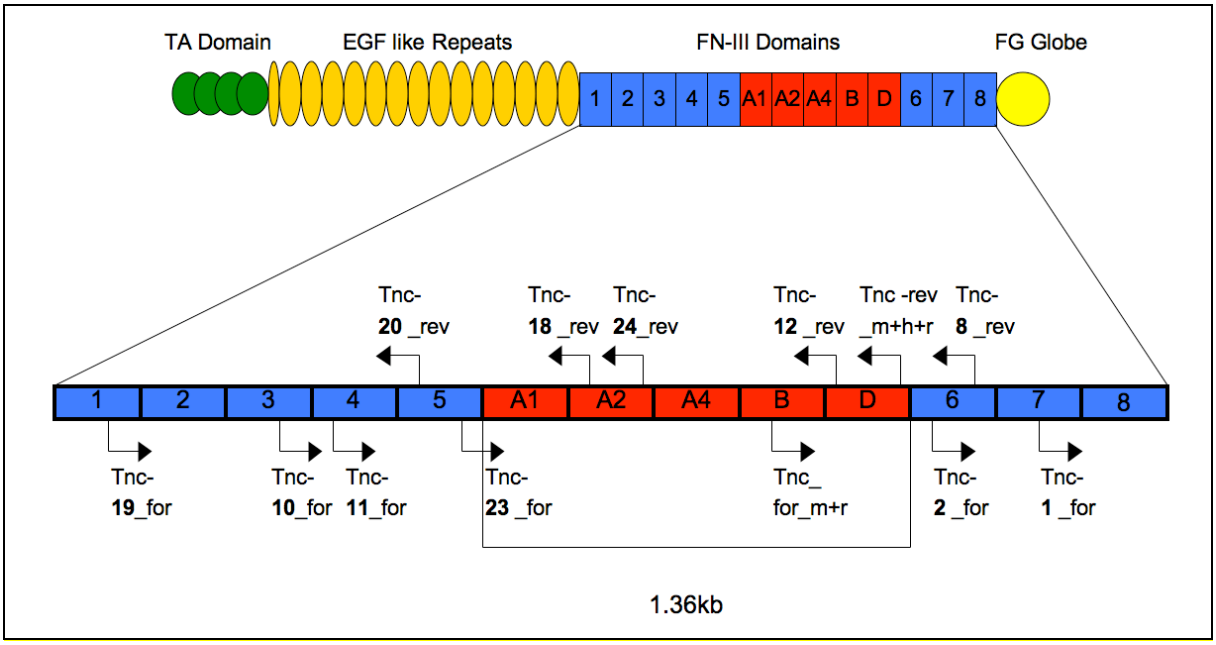

Figure 14. *Schematic diagram of primer sets used for sequencing of the alternative spliced FN-III domains (TA domain = tenascin assembly domain, EGF-L repeats = epidermal growth factor like repeats, FN-III domains = fibronectin type III domains, FG = fibrinogen globe).*

Four different TN-C isoforms, which are up-regulated post myocardial infarction in myocardial scar tissue were identified (*Figure 15.).* Those isoforms arise from alternative splicing of FN-III domains. Sizes of single FN-III domains vary between 269bp and 274bp. In the smallest identified isoform all 5 FN-III domains (A1, A2, A4, B, and D) with a common size of 1.365bp were removed (*Figure 16.*). In one isoform only FN-III domain D was included and one isoform comprised domain B and D in the alternative spliced region.

Rat cDNA sequence shares 94% identical residues with the murine and 83% with the human sequence. In comparison, rat protein sequence shares 95% identical amino

acids with the murine and 70% with the human TN-C sequence.

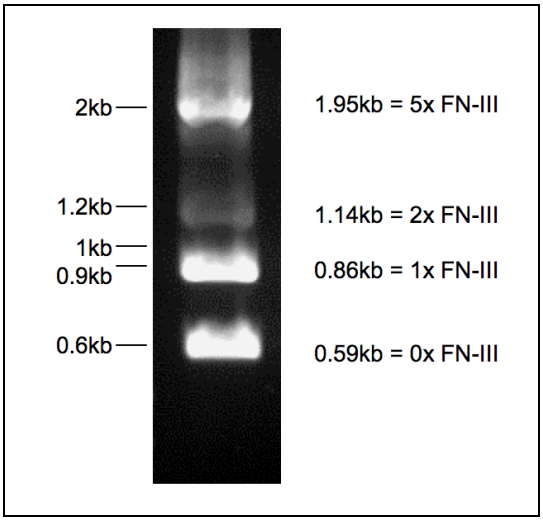

Figure 15. *PCR products of 4 identified TN-C isoforms, with 5, 2, 1, and none FN-III domains in the alternative spliced region, which were up-regulated 7 days post infarction (primer: Tnc-8_rev and Tnc-11_for; FN-III domains = fibronectin type III domains).*

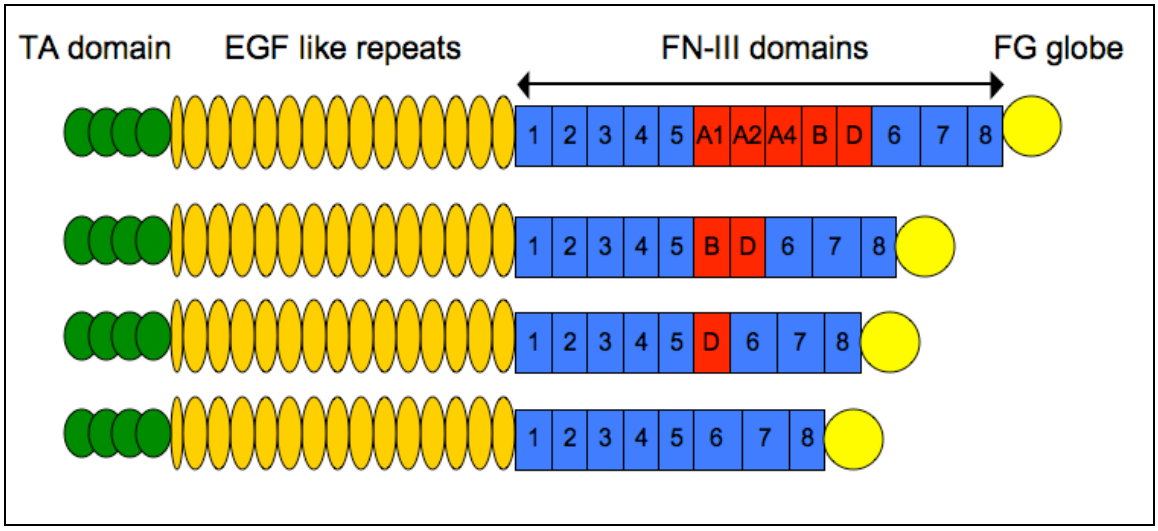

Figure 16. *Structural composition of 4 TN-C isoforms identified after myocardial infarction (TA domain = tenascin assembly domain, EGF-L repeats = epidermal growth factor like repeats, FN-III domains = fibronectin type III domains, FG = fibrinogen globe).*

3.2. PCR Results

PCR analysis not only showed an up-regulation of different spliced TN-C isoforms, moreover a time dependent shift in isoform expression was demonstrated (*Figure 17.*).

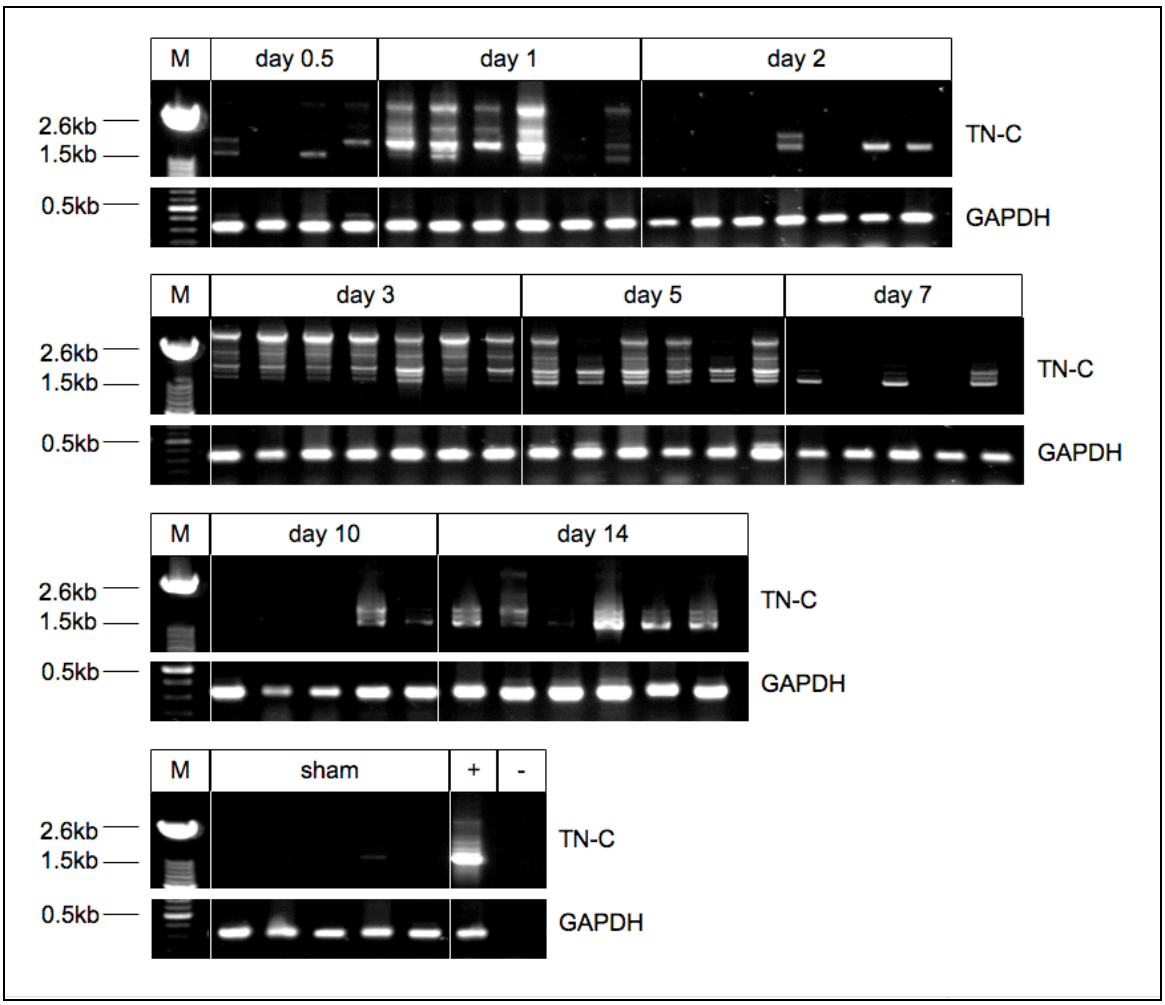

Figure 17. *PCR results of scar tissue including groups of 0.5 to 14 days post myocardial infarction and free wall samples of sham controls (primer: Tnc-26_rev and Tnc-23_for were used resulting in 4 fragments with about 2.958bp, 2.128bp, 1.863bp and 1.593bp. GAPDH was used as control = 331bp).*

Even 12h post MI TN-C level was slightly increased, but only small isoforms (PCR products with 1.863bp and 1.593bp) were present. Four isoforms were identified 24

hours post infarction and decreased 2 days post MI, where again only the small isoforms were observable. Expression of the large TN-C isoform (PCR product with 2.958bp) peaked at time point 3. Five days after infarction the large isoform was still present. Whereas, 7, 10, and 14 days post MI the large isoforms were down-regulated and only small isoforms dominate.
In contrast, within the sham group only the small isoform is slightly existent. In non-infarcted free wall tissue of the sham control group the large isoform is completely absent. GAPDH was used as positive control.

3.3. Real Time-PCR Results

For real time-PCR analysis primer Tnc_for and Tnc-rev (*Figure 13.*), located in the EGF like repeats, were used resulting in a 60bp fragment. Total TN-C mRNA level was analysed and no determination was made between different isoforms.
In the infarcted region real time-PCR analysis showed 12h after infarction only a basis level of TN-C mRNA (*Figure 18.a.*). Twenty-four hours post MI TN-C level was slightly increased. A significant TN-C mRNA up-regulation was observable 2 days post infarction that peaked at day 3 (day 1 vs. 2: $^{**}p < 0.01$; day 1 vs. 3: $^{***}p < 0.001$) followed by a decrease at day 5 (day 2 vs. 5: $^{**}p < 0.01$). At day 7 and 10 mRNA level increased again (day 0.5 vs. 7: $^{**}p < 0.01$; day 5 vs. 10: $^{*}p < 0.05$; day 0.5 vs. 10: $^{***}p < 0.001$; day 1 vs. 10: $^{*}p < 0.05$) and 2 weeks after infarction TN-C level was clearly down-regulated (day 2 vs. 14: $^{***}p < 0.001$; day 7 vs. 14: $^{**}p < 0.01$; day 10 vs. 14: $^{***}p < 0.001$) and comparable with basis level at day 0.5 after MI.
In contrast to tissue from the infarcted region, in free wall samples of the left ventricle TN-C level was barely observably. Only 3 and 5 days post MI TN-C level significant increased ($^{**}p < 0.01$; *Figure 18.b.*).

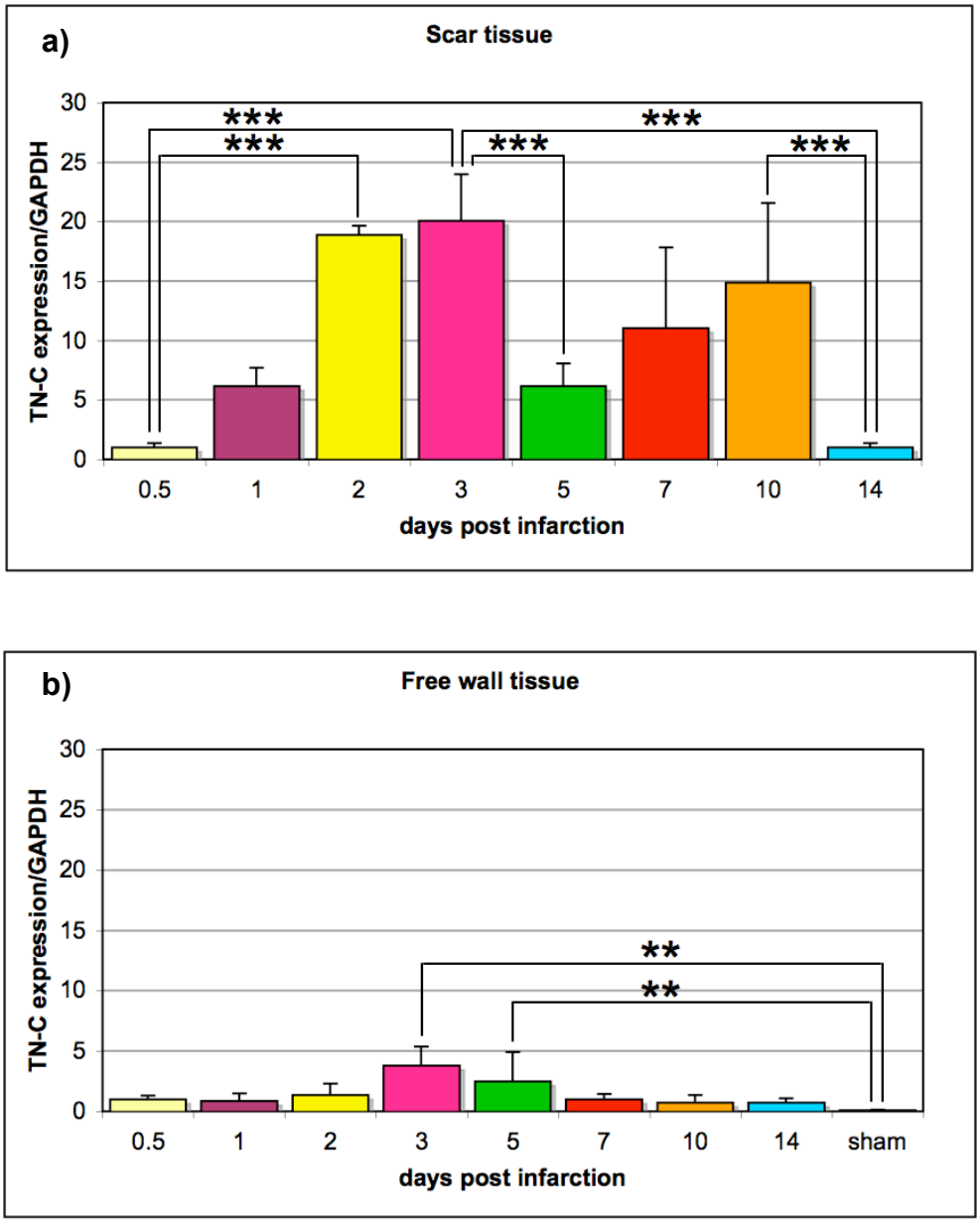

Figure 18. *Real time-PCR results from* ***(a.)*** *scar tissue (***p < 0.001), and* ***(b.)*** *non-infarcted, free wall areas (**p < 0.01) including groups of 0.5 to 14 days after myocardial infarction. A sham group was used as negative control. Details of results were described in the text.*

3.4. Histological and Immunohistochemical Analyses

In healthy, adult cardiac tissue TN-C is not expressed, but under pathological conditions such as myocardial infarction the protein was up-regulated within 12h.

3.4.1. Morphometric Studies

For infarct size measurement histological cross sections from time point 0.5 to 14 days after MI were used. *Table 6.* summarises results from morphometrical analysis. Infarct size was at an average of 34.96 ± 9.17% of the left ventricle. Sham operated controls, without myocardial infarction, were used as negative control.

Days post infarction	Infarct size (mean ± SD)
0.5	30.79 ± 6.13%
1	37.32 ± 10.60%
2	47.08 ± 8.07%
3	39.92 ± 7.38%
5	28.23 ± 5.09%
7	33.98 ± 9.01%
10	32.12 ± 4.90%
14	30.26 ± 5.38%
Sham control	0%

Table 6. *Results from infarct size measurement of the left ventricle including groups of 0.5 to 14 days after myocardial infarction and a sham operated control group.*

In addition thinning of scar tissue was measured after MI (*Figure 19.).* Scar tissue diameter peaked at day 2 post infarction (day 0.5 vs. 2: **$p < 0.01$). Starting 5 days

post MI significant thinning of the left ventricle was noticeable (day 2 vs. 5, 10 and 14: ***p < 0.001; day 2 vs. 7: **p < 0.01; day 3 vs. 5: *p < 0.05; day 3 vs. 14: **p < 0.01).

Cross sections of septum samples including groups of 0.5 to 14 days post infarction showed no difference compared to sham controls (p = ns; *Figure 20.*).

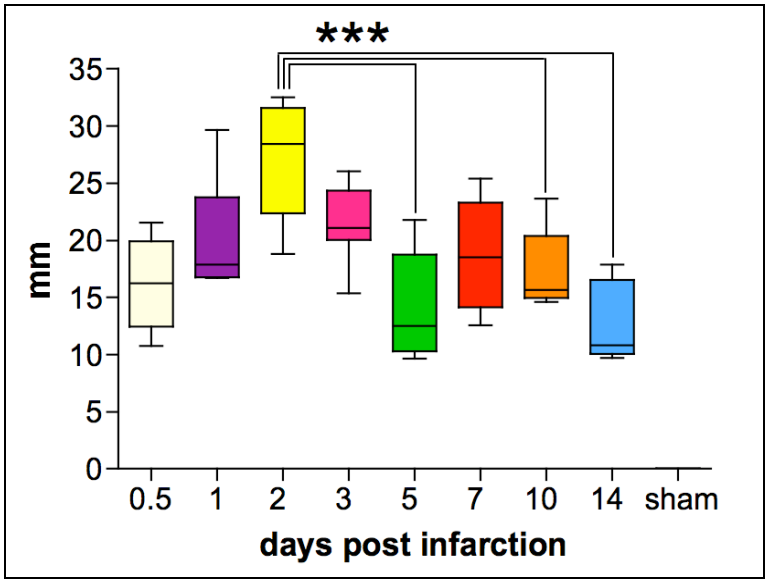

Figure 19. *Results from scar cross section measurement including groups of 0.5 to 14 days after myocardial infarction and a sham operated control group (***p < 0.001).*

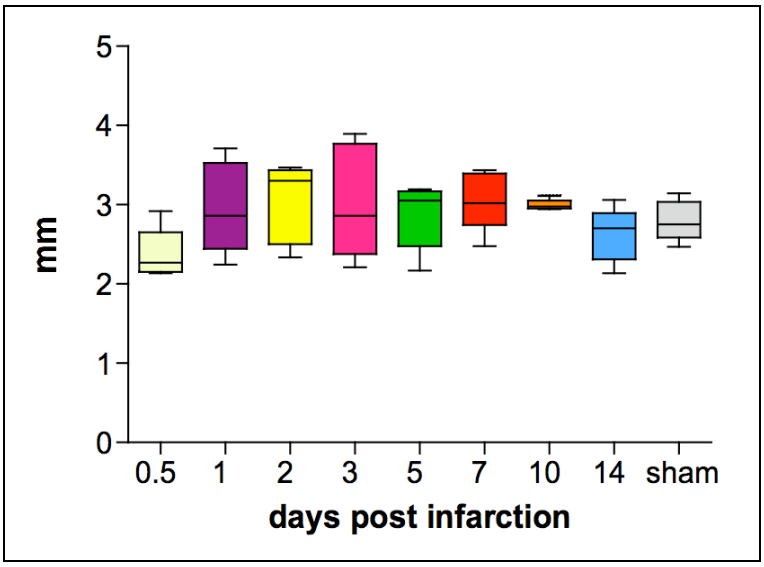

Figure 20. *Results from septum cross section measurement including groups of 0.5 to 14 days after myocardial infarction and a sham operated control group (p = ns).*

Cross sections taken from sham operated control animals were completely negative for TN-C staining (*Figure 21.c.*). Twelve hours after MI little amounts of TN-C protein were noticeable in the border zone between infarcted and non-infarcted regions (*Figure 21.f.* and *24.b.).* Twenty-four hours post infarction *(Figure 21.i.*) TN-C protein level increased, peaked at day 7 (*Figure 23.c.*) after MI and than slightly decreased at time point 10 and 14 *(Figure 23.f.* and *i.).* Two weeks post MI a collagen based solid scar is formed (*Figure 23.g., h.,* and *i.*).

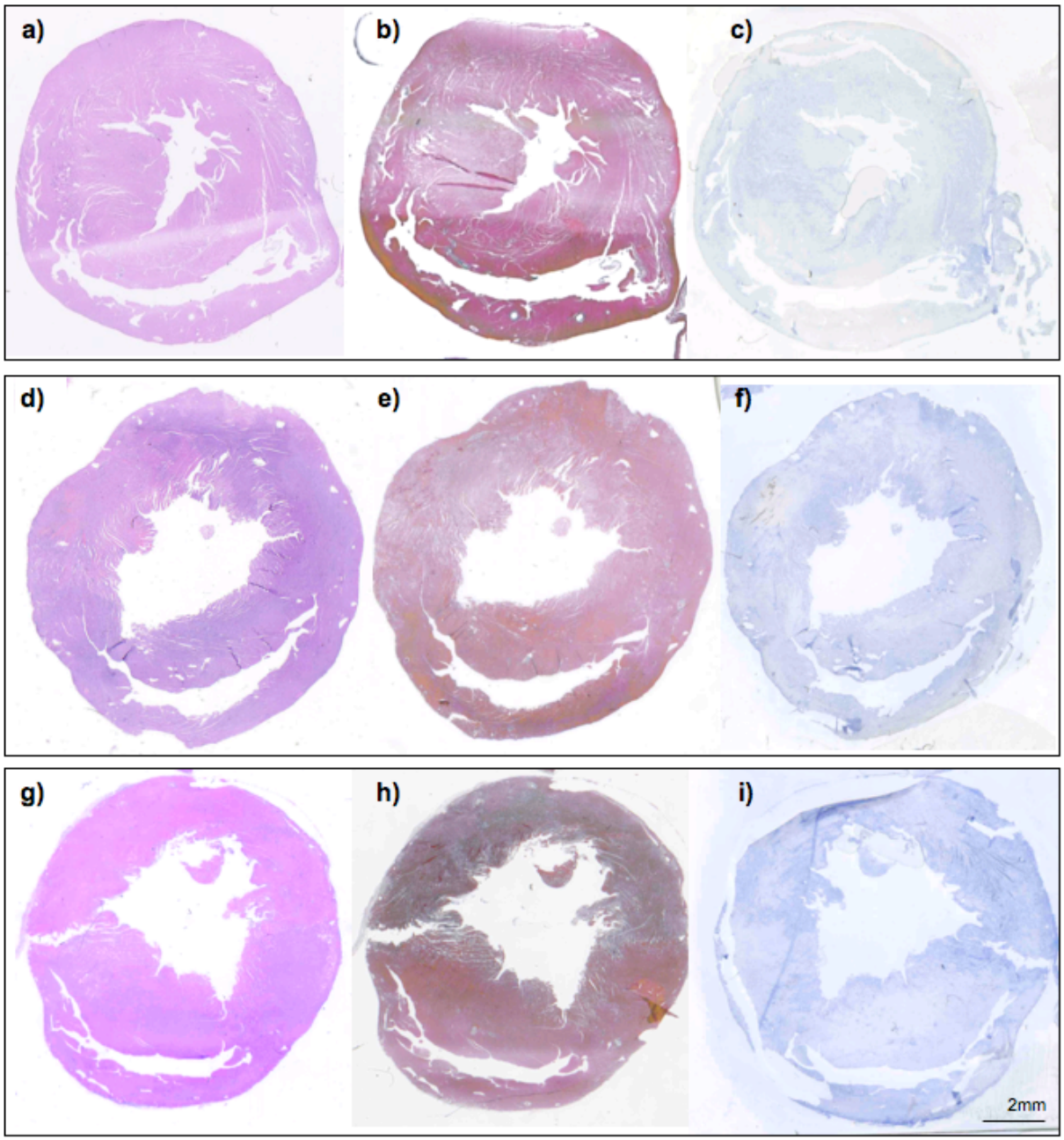

Figure 21. ***(a., d.,*** *and* ***g.)*** *H&E staining,* ***(b., e.,*** *and* ***h.)*** *Trichrome (Goldner) staining, and* ***(c., f.,*** *and* ***i.)*** *TN-C staining.* ***(a., b.,*** *and* ***c.)*** *Sham control,* ***(d., e.,*** *and* ***f.)*** *12 hours, and (****g., h.,*** *and* ***i.)*** *24 hours post myocardial infarction.*

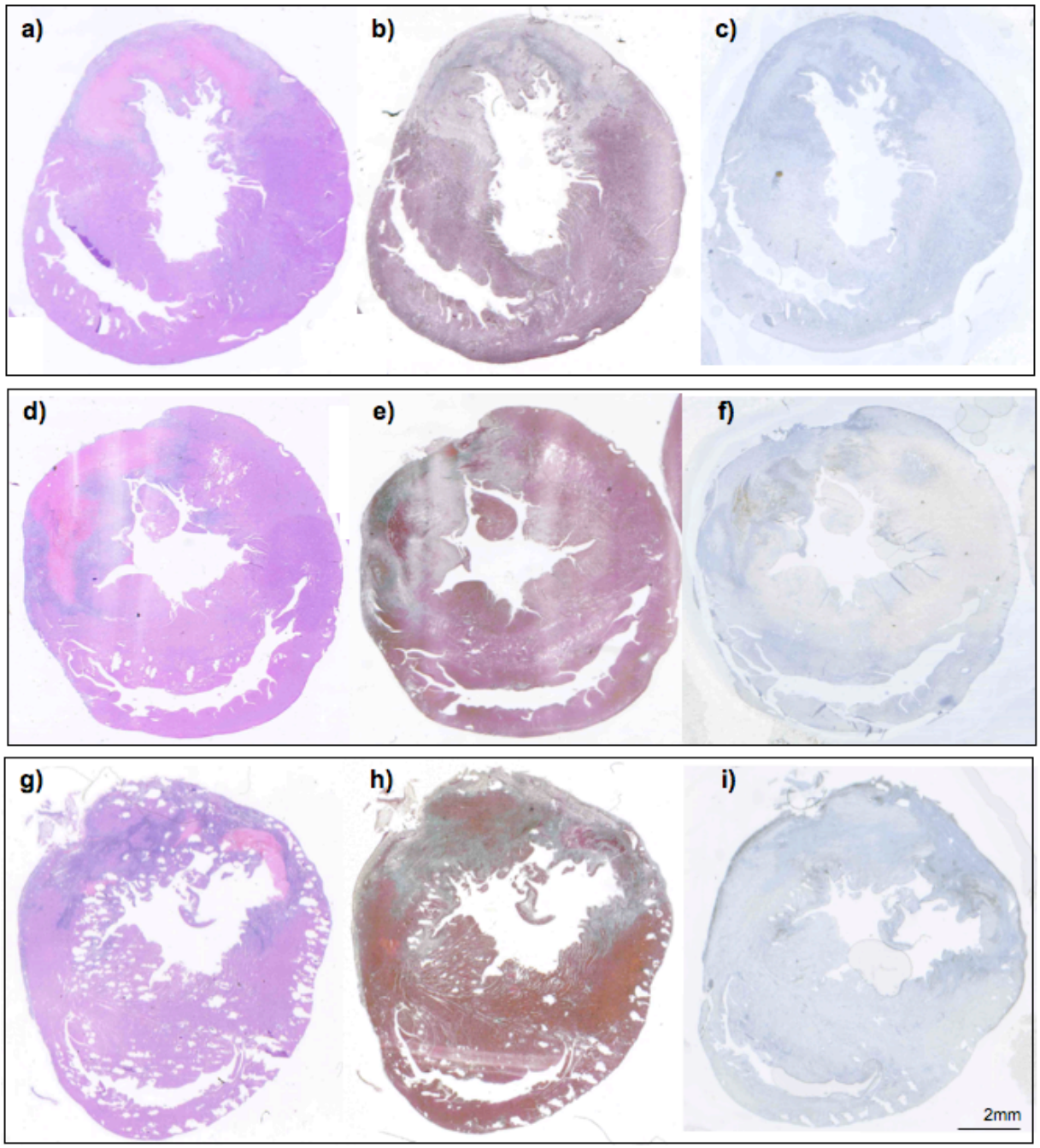

Figure 22. ***(a., d.,*** *and* ***g.)*** *H&E staining,* ***(b., e.,*** *and* ***h.)*** *Trichrome (Goldner) staining, and* ***(c., f.,*** *and* ***i.)*** *TN-C staining.* ***(a., b.,*** *and* ***c.)*** *2 days,* ***(d., e.,*** *and* ***f.)*** *3 days, and* ***(g., h.,*** *and* ***i.)*** *5 days post myocardial infarction.*

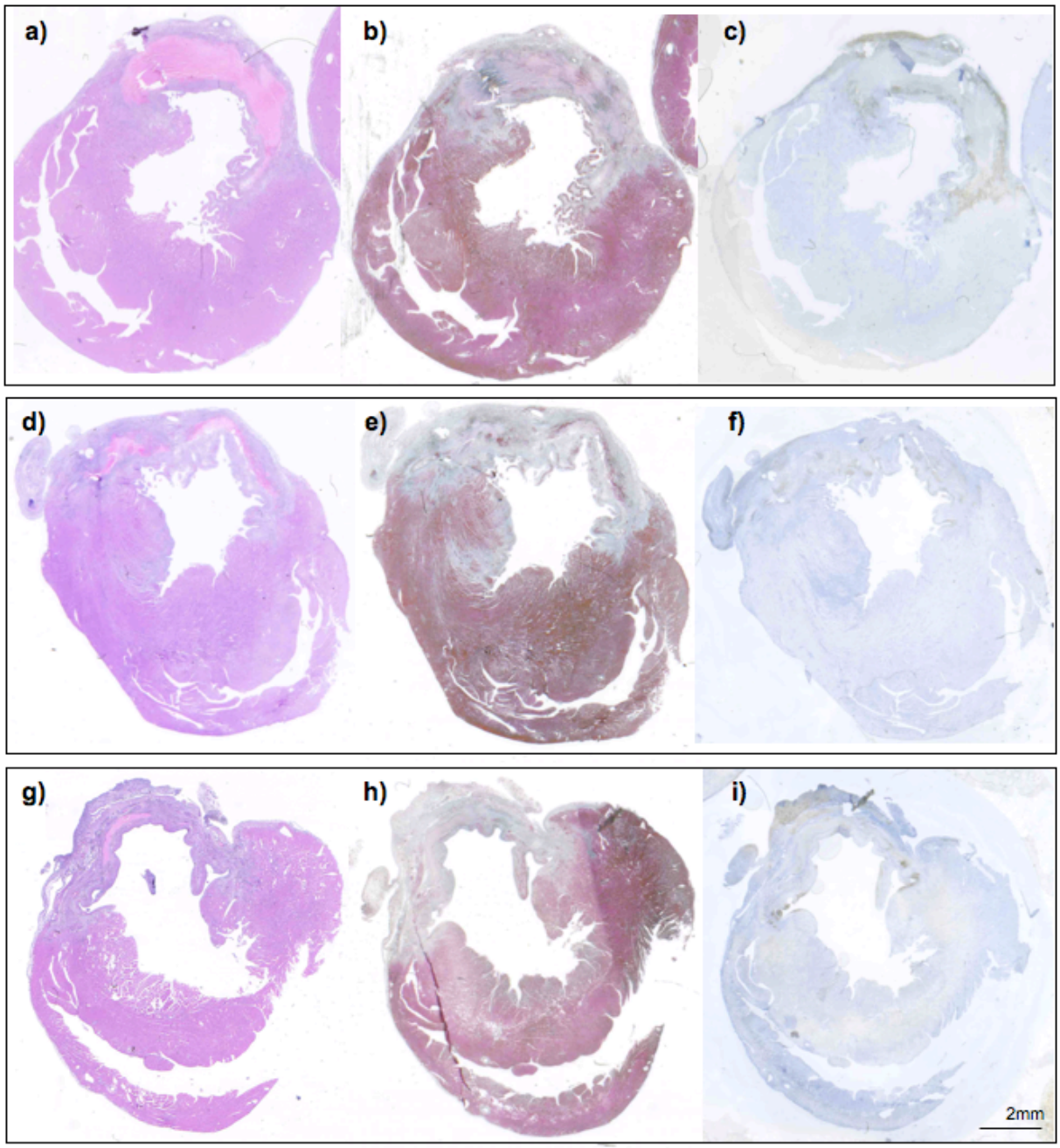

Figure 23. ***(a., d.,*** *and* ***g.)*** *H&E staining,* ***(b., e.,*** *and* ***h.)*** *Trichrome (Goldner) staining, and* ***(c., f.,*** *and* ***i.)*** *TN-C staining.* ***(a., b.,*** *and* ***c.)*** *7 days,* ***(d., e.,*** *and* ***f.)*** *10 days, and* ***(g., h.,*** *and* ***i.)*** *14 days post myocardial infarction.*

3.4.2. TN-C and Trichrome (Goldner) Staining

At time points 0.5 to 2 days post infarction TN-C protein was slightly present in the border zone, whereas the infarcted region was complete negative for TN-C staining (*Figure 24.b.* and *c., Figure 25.b.* and *c.*, black arrows).

Trichrome (Goldner) staining demonstrates total collagen deposition (shown in light green). From 2 to 3 days post infarction collagen fibre accumulation was observed in the infarcted region (*Figure 25.a.,* and *Figure 26.a.*).

Three days post MI TN-C staining slightly increased in the marginal zone and the infarcted area was still TN-C negative (*Figure 26.b.,* black arrows).

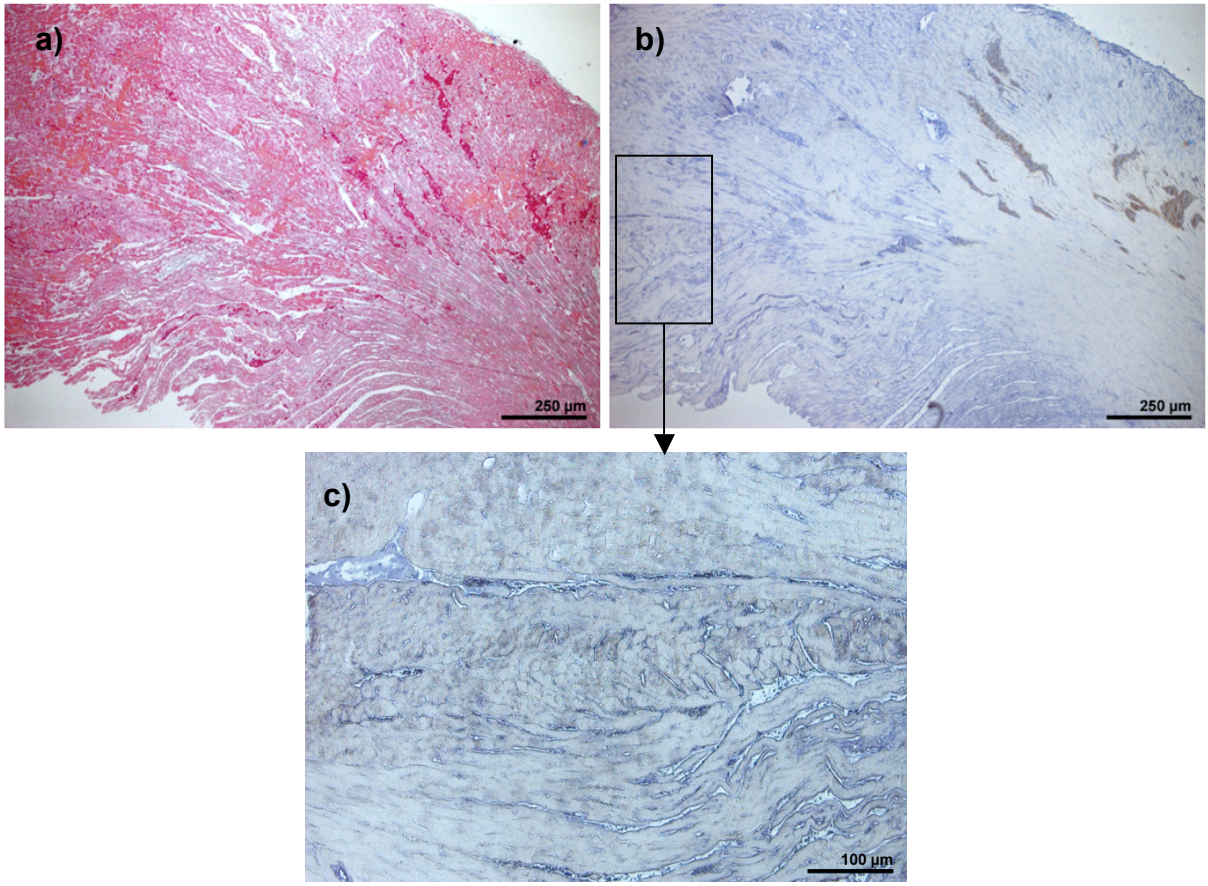

Figure 24. (a.) *Trichrome (Goldner) staining, and* ***(b.*** *and* ***c.)*** *TN-C staining 12 hours post myocardial infarction.* ***(c.)*** *Enlarged image of serial sections.*

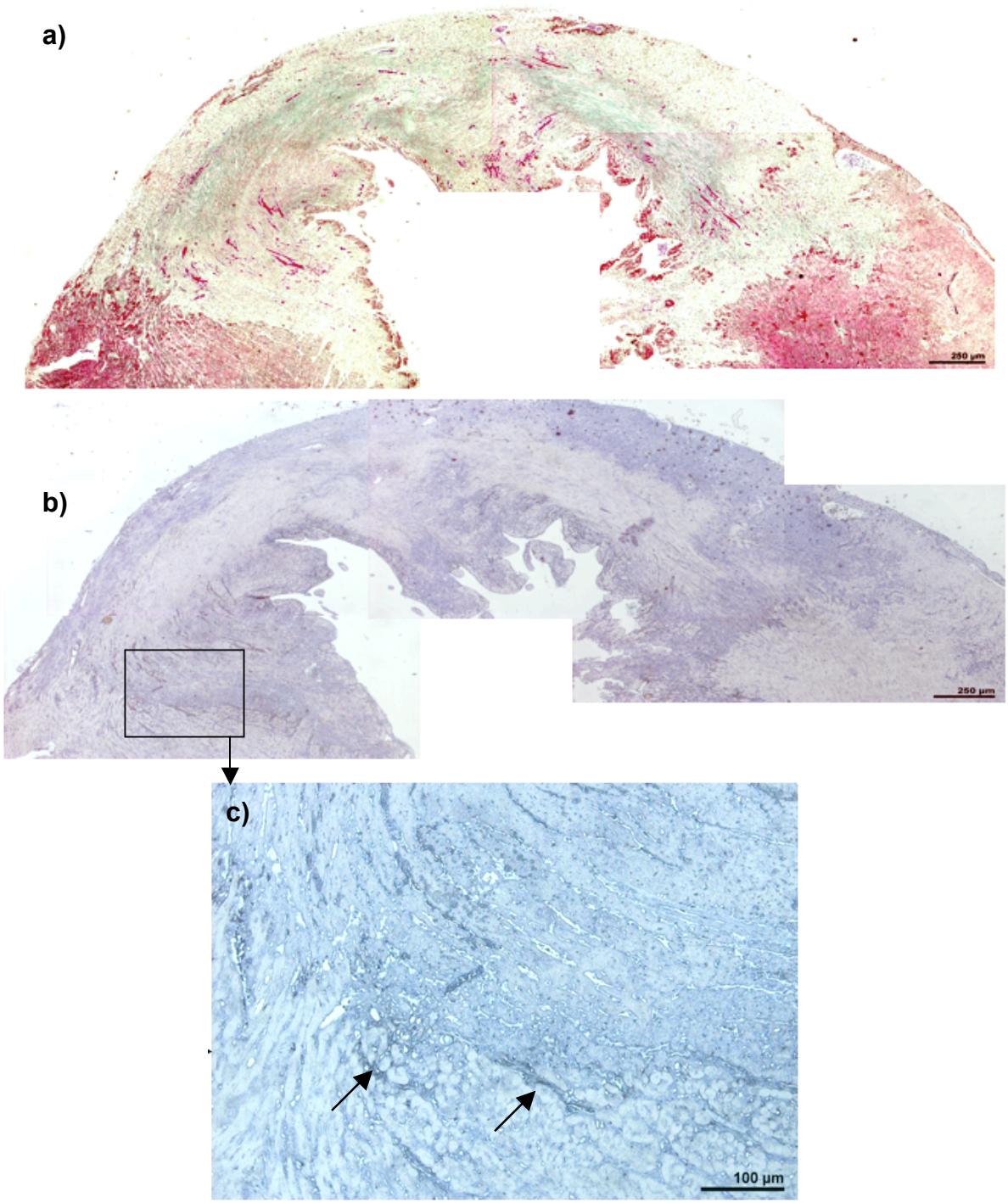

Figure 25. (a.) *Trichrome (Goldner) staining, and* ***(b.*** *and* ***c.)*** *TN-C staining 2 days post infarction (black arrows).* ***(c.)*** *Enlarged image of serial sections.*

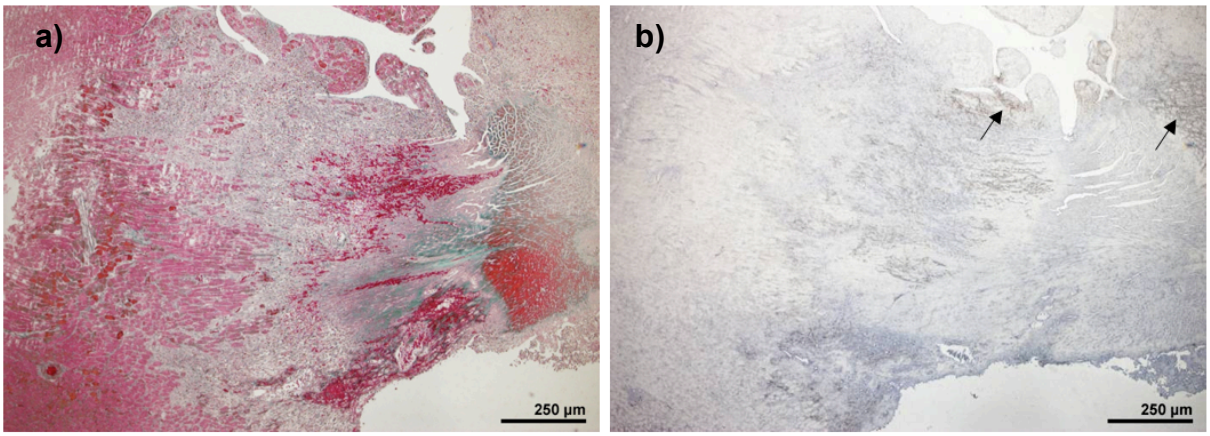

Figure 26. (a.) *Trichrome (Goldner) staining, and* ***(b.)*** *TN-C staining 3 days after myocardial infarction (black arrows).*

Five days after MI collagen staining was still positive within the infarcted region but prominent shifted in the border zone between infarcted and non-infarcted region (*Figure 27.a. and c.*).

Interestingly, at day 5 and 7 post MI TN-C staining and collagen staining showed a very similar localisation pattern within the border zone (*Figure 27.* and *Figure 28.*). At day 7 post MI TN-C staining reached the maximum level (*Figure 28.b., d.,* and *f.).* Seven days post infarction TN-C was expressed around healthy cardiomyocytes in areas where infiltrations were located (*Figure 29.a.* and *b.*).

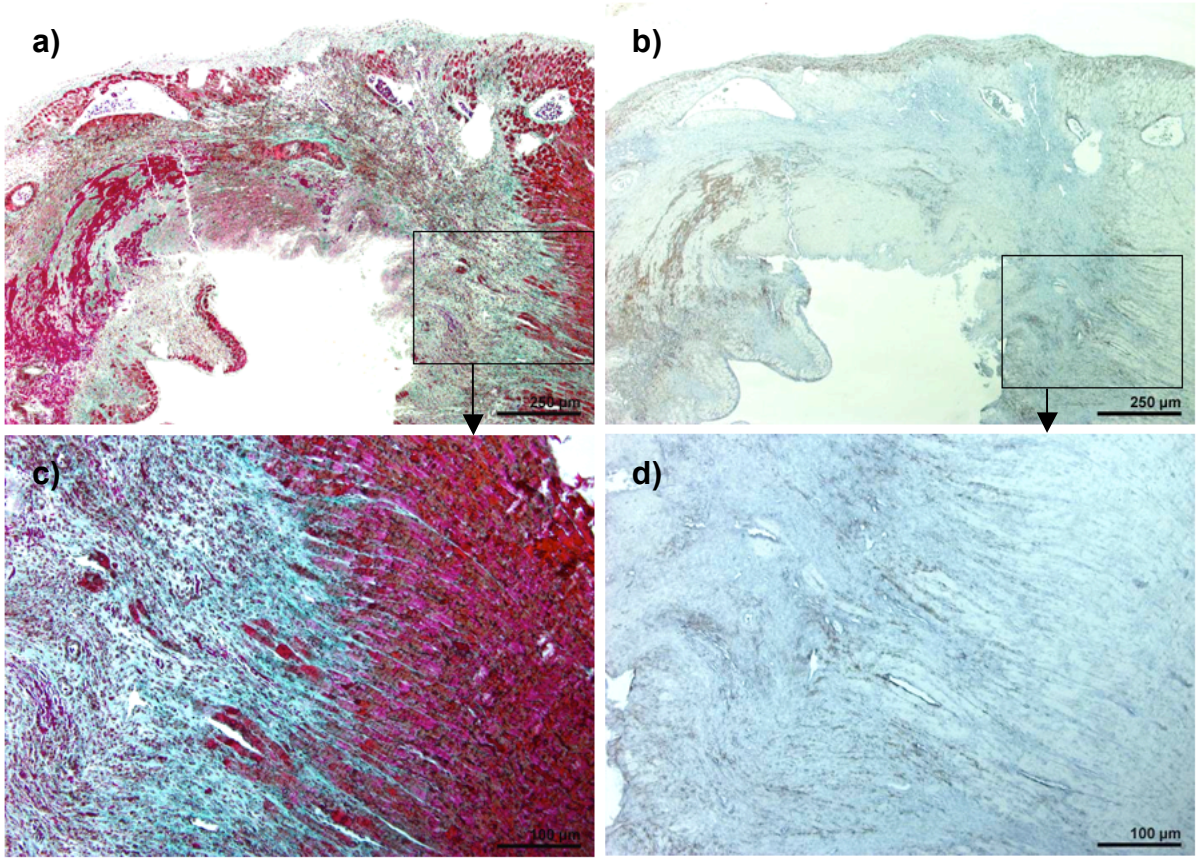

Figure 27. ***(a.*** *and* ***c.)*** *Trichrome (Goldner) staining, and* ***(b.*** *and* ***d.)*** *TN-C staining 5 days post myocardial infarction.* ***(c.*** *and* ***d.)*** *Enlarged images of serial sections of the myocardial infarction border zone.*

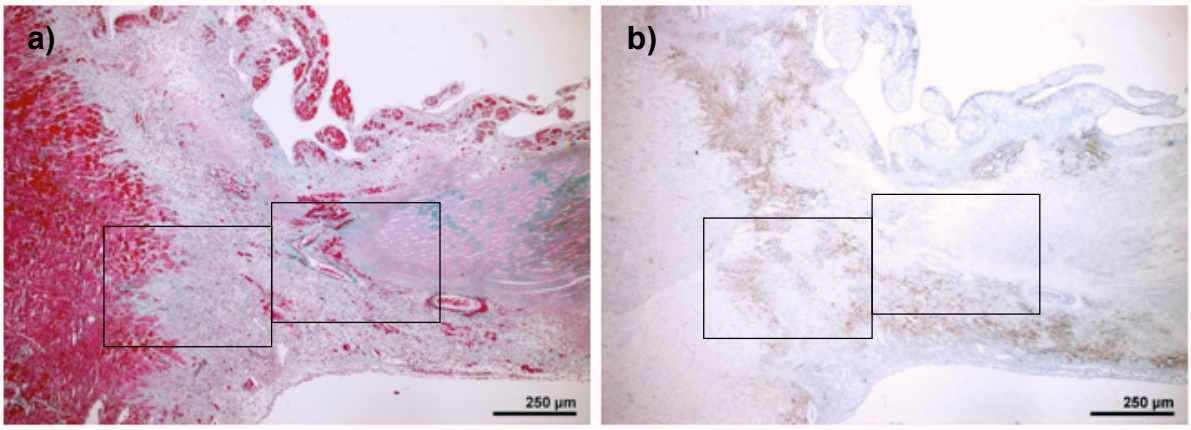

Continued on next page.

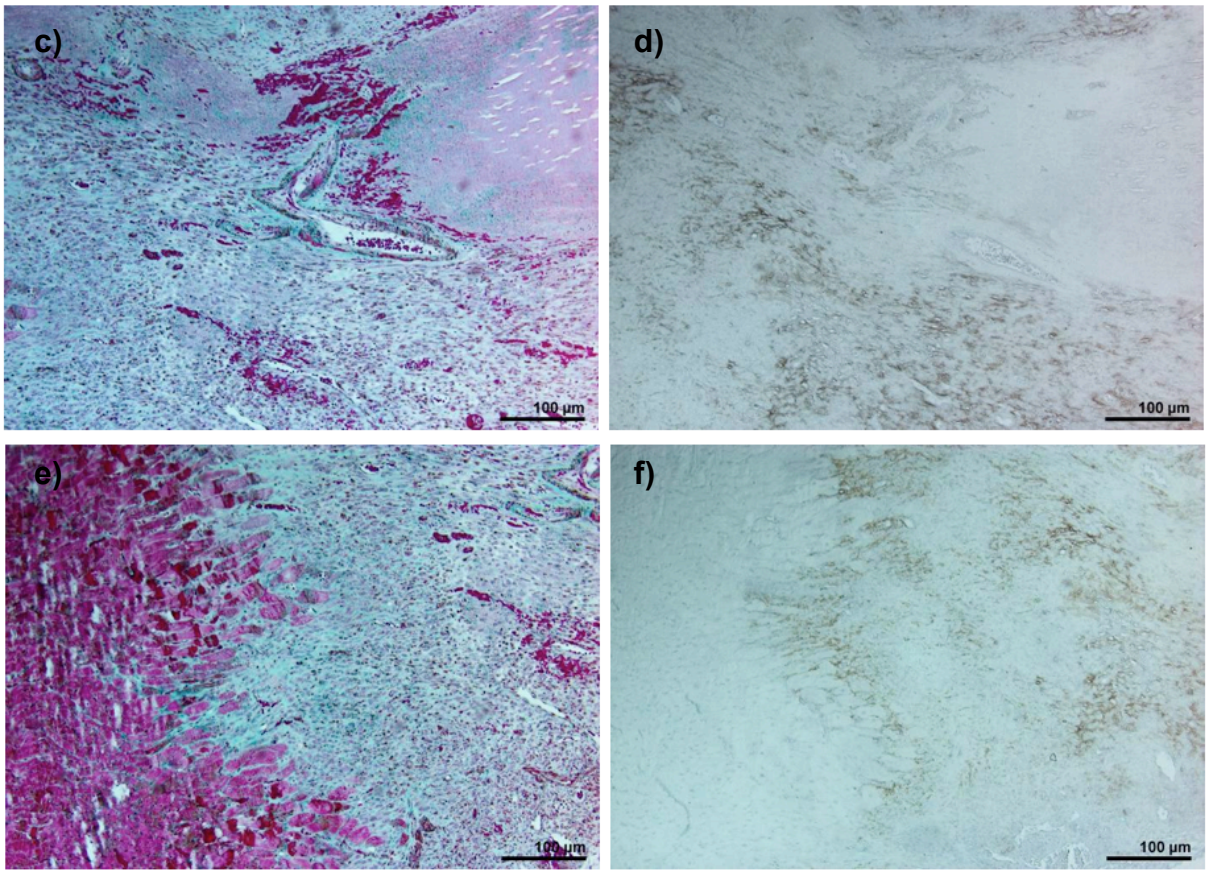

Figure 28. (a., c., *and* ***e.)*** *Trichrome (Goldner) staining, and* ***(b., d.,*** *and* ***f.)*** *TN-C staining 7 days post myocardial infarction.* ***(c., e., d., and f.)*** *Enlarged images of serial sections of the myocardial infarction border zone.*

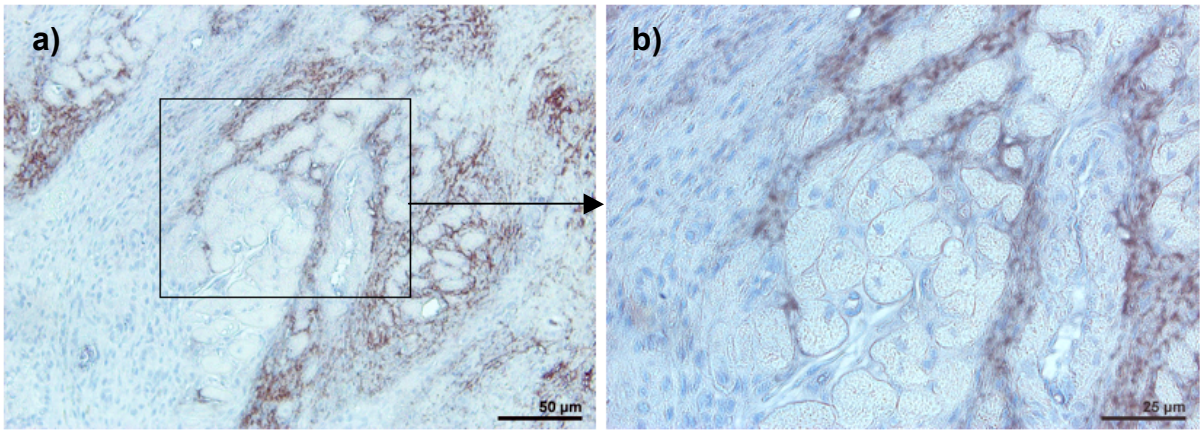

Figure 29. (a. *and* ***b.)*** *TN-C staining 7 days post myocardial infarction.* ***(b.)*** *Enlarged image of serial section.*

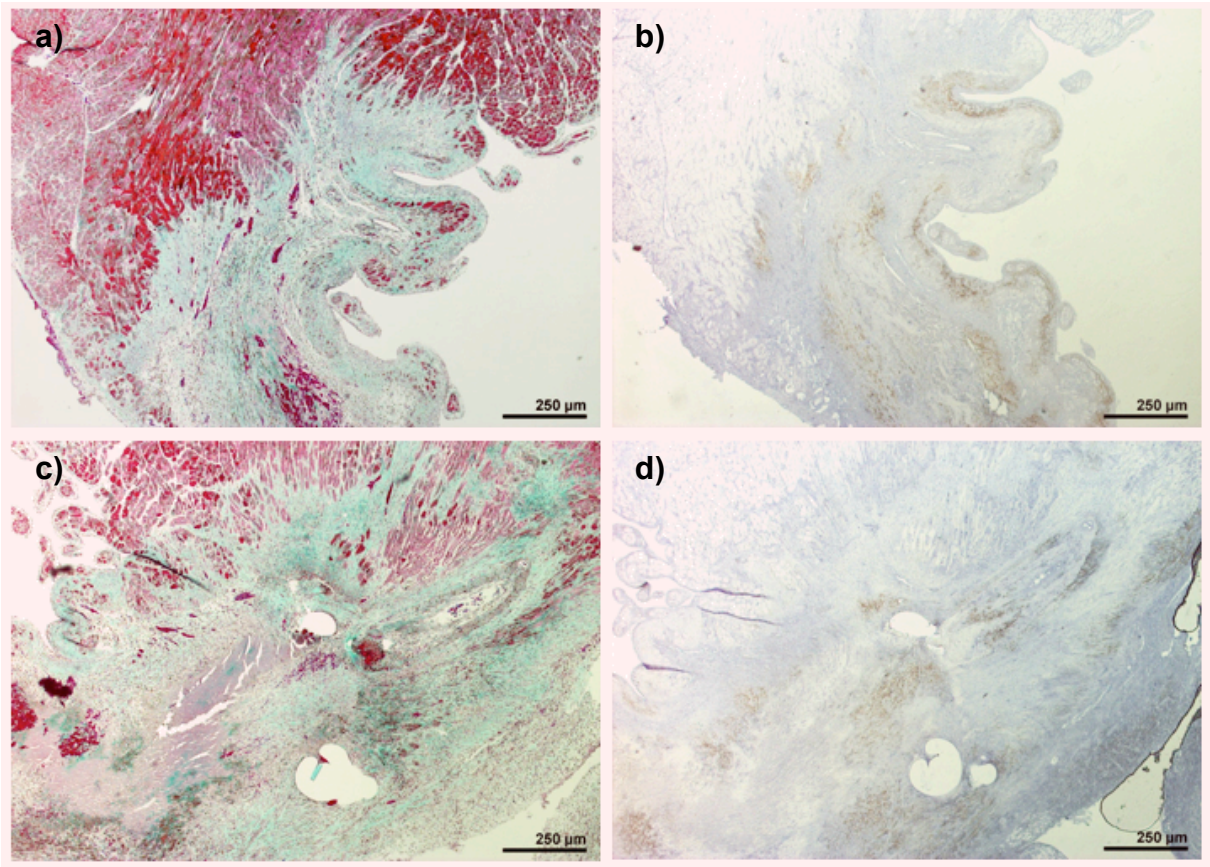

***Figure 30. (a.** and **c.)** Trichrome (Goldner) staining, and **(b.** and **d.)** TN-C staining 10 days after myocardial infarction.*

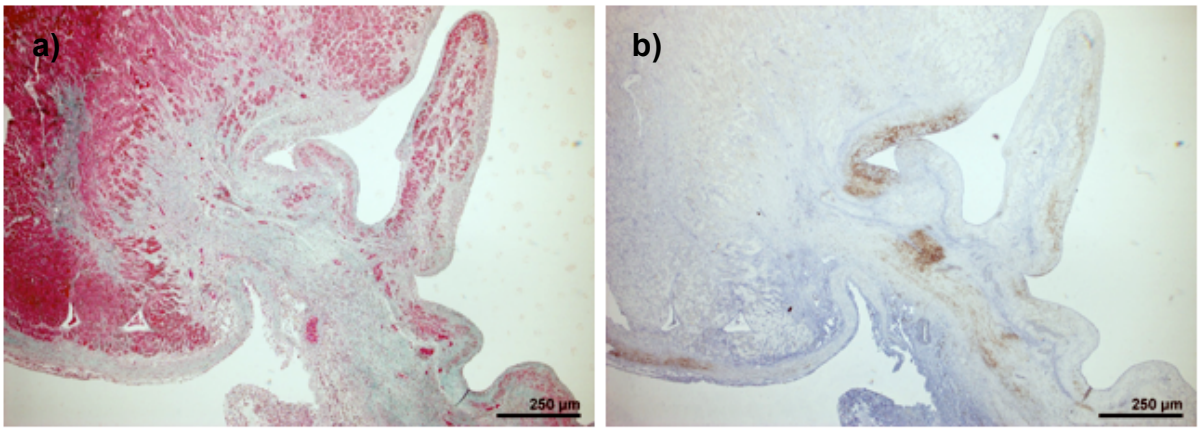

***Figure 31. (a.)** Trichrome (Goldner) staining, and **(b.)** TN-C staining 2 weeks after myocardial infarction.*

Ten days after MI collagen fibre accumulation was mainly visible in the border zone (*Figure 30.a.* and *c.)* and TN-C protein level clearly decreased (*Figure 30.b.* and *d*.). Therefore, 14 days post infarction TN-C expression was only slightly visible in the border zone between infarcted and non-infarcted areas (*Figure 31.b.*). Within the sham control group no TN-C expression was detectable at all (*Figure 32.b.*).

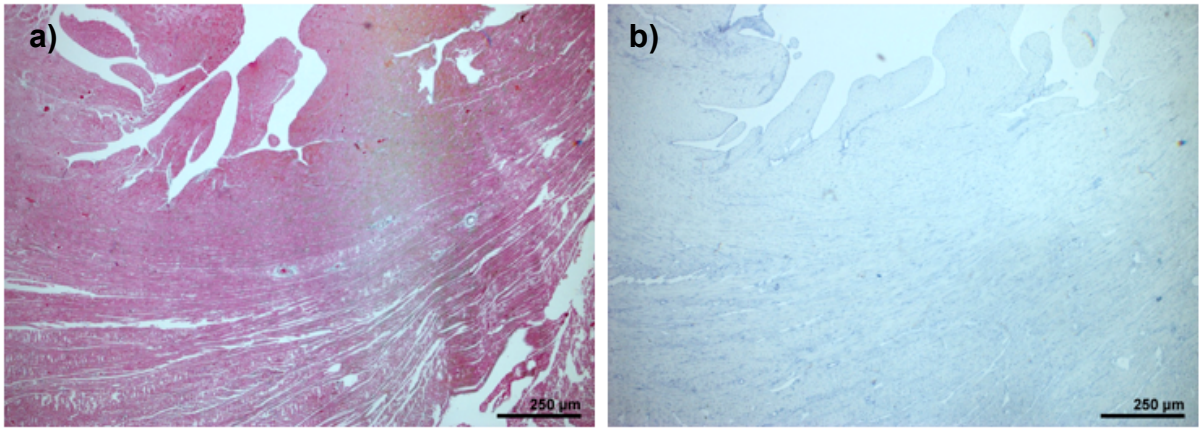

Figure 32. (a.) *Trichrome (Goldner) staining, and* ***(b.)*** *TN-C staining of sham controls.*

3.4.3. TN-C Staining of Control Organs

TN-C expression pattern was analysed within kidney, liver, lung, and spleen tissues. Protein distribution 7 days after infarction was compared to sham controls.

TN-C staining of kidneys from sham controls was positive for TN-C (*Figure 33.a*.). Kidney medulla showed TN-C immunoreactivity in the tubule interstitial spaces. TN-C level 7 days post MI increased compared to controls (*Figure 33.b.)*

Normal liver samples showed weak, discontinuous sinusoidal TN-C staining (*Figure 34.a.).* Staining of liver tissue 7 days post MI showed more TN-C positive (*Figure 34.b.)* areas compared to the sham control group.

Normal tissue samples from rat lungs (*Figure 35.a.)* and 7 days post infarction (*Figure 35.b.,* black arrows*)* were barely positive for TN-C staining.

Spleens showed positive TN-C staining in the marginal zones and the capillaries of both groups, 7 days after infarction (*Figure 36.b.* and *c.,* black arrow*)* and sham controls (*Figure 36.a.).*

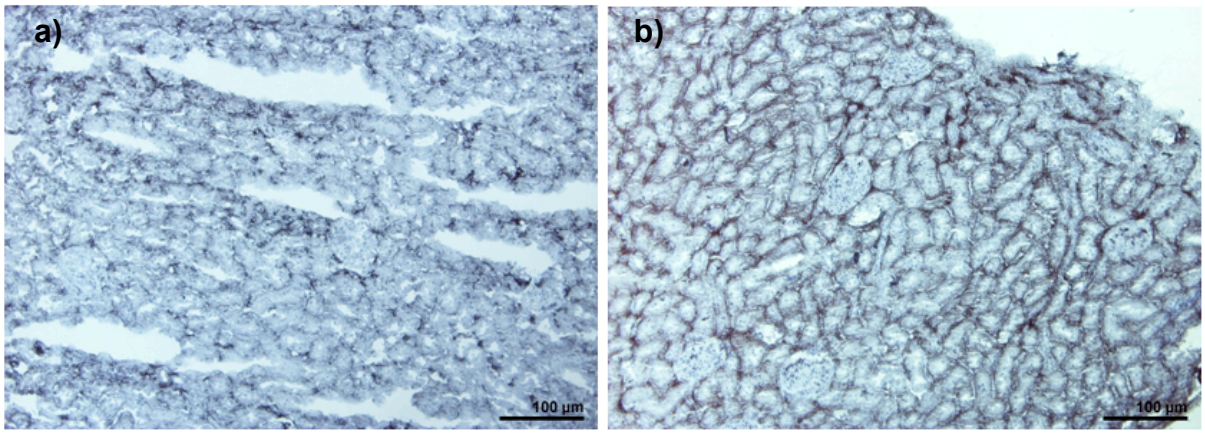

Figure 33. *TN-C staining of kidney tissue from* ***(a.)*** *sham control, and* ***(b.)*** *7 days post myocardial infarction.*

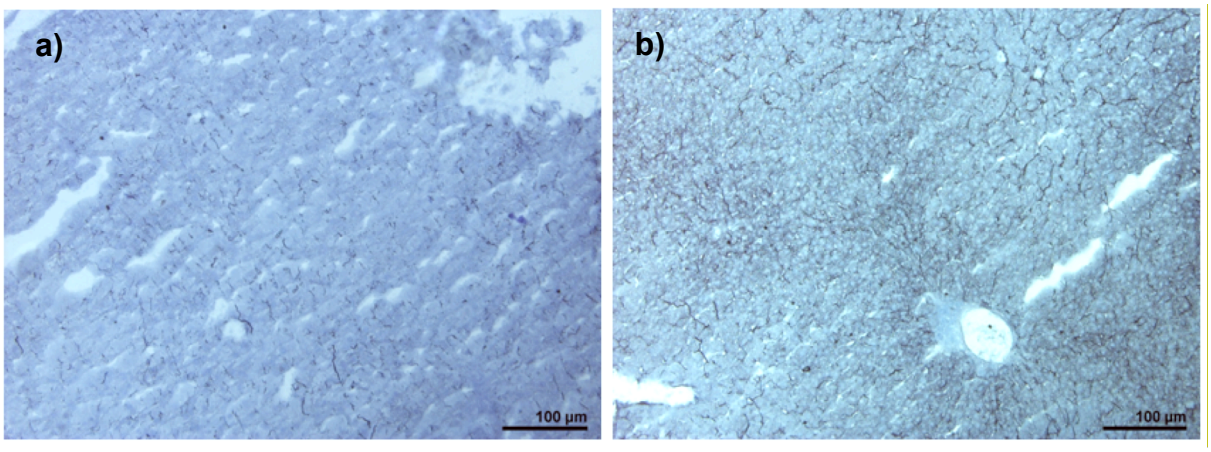

Figure 34. *TN-C staining of liver tissue from* ***(a.)*** *sham control, and* ***(b.)*** *7 days post myocardial infarction.*

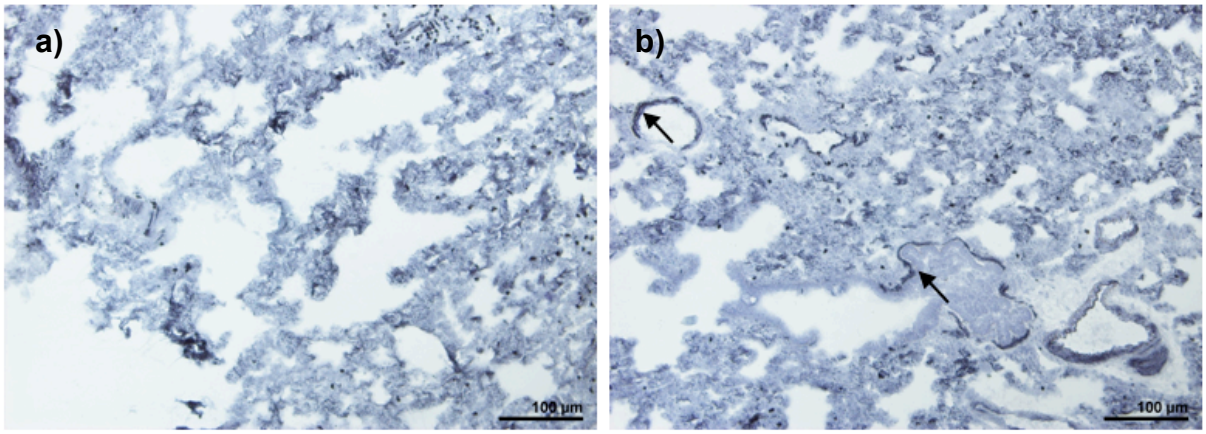

Figure 35. *TN-C staining of lung tissue from* ***(a.)*** *sham control, and* ***(b.)*** *7 days post myocardial infarction (black arrow).*

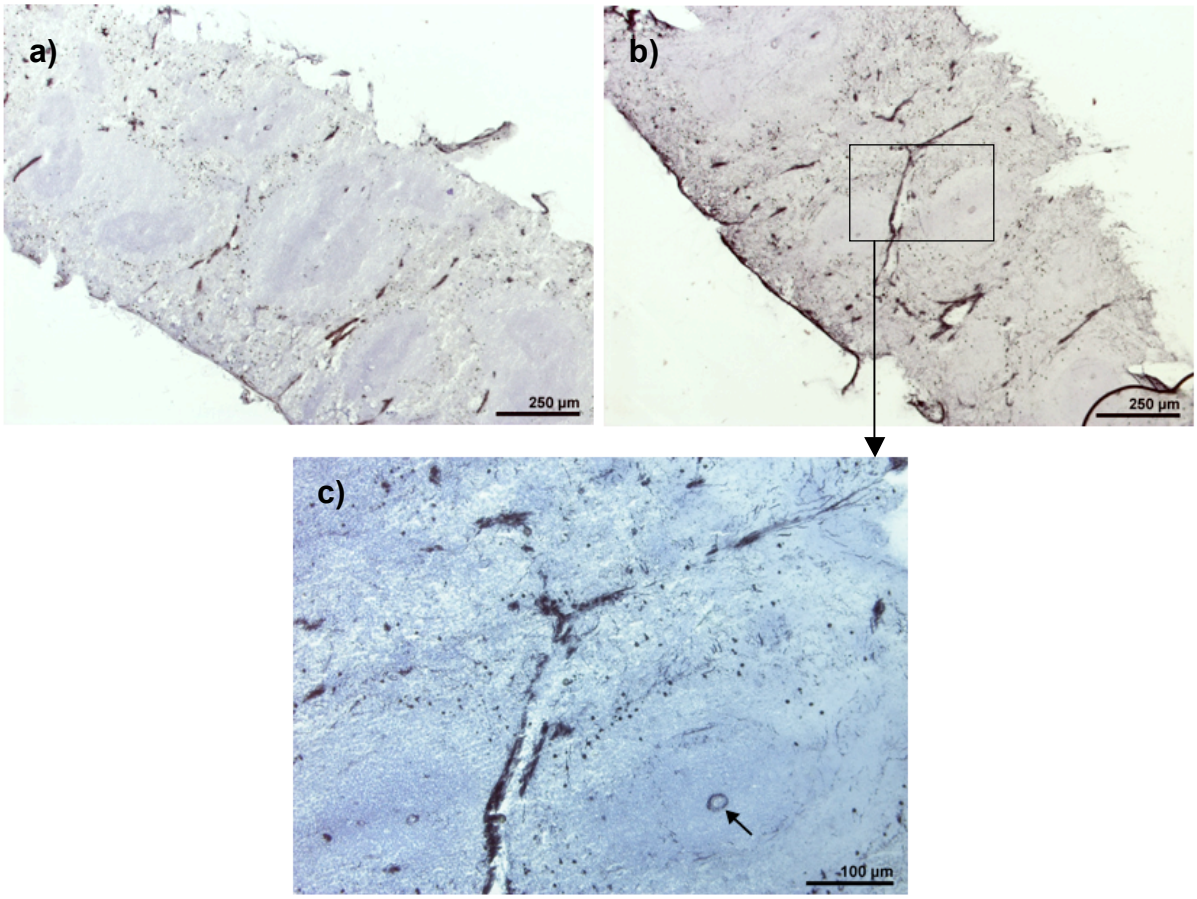

Figure 36. *TN-C staining of spleen tissue form* ***(a.)*** *sham control, and* ***(b.*** *and* ***c.)*** *7 days post myocardial infarction (black arrow).* ***(c.)*** *Enlarged image of serial section.*

3.5. Western Blot Results

Western blots were loaded with myocardial tissue lysates (15µg) isolated from scar tissue including time points 0.5 to 14 days post MI. Free wall samples of the left ventricle of sham controls were used as negative control and β-actin was used as loading control. Purified human TN-C, which migrates around 280-300kDa, was used as positive control and for standardisation.

In western blot experiments especially two different TN-C isoforms were detectable in the infarcted area of the left ventricle post MI. Those isoforms have an apparent molecular weight of 230kDa and 270kDa.
A time dependent shift and, additionally, a shift in TN-C isoform expression were observable.
Twelve hours to 14 days after MI the smaller isoform was slightly detectable in the infarcted region, but no significant differences were observed in comparison to the sham control group (p = ns; *Figure 37.a*.).
In contrast to the expression of the small TN-C isoform, 12h and 24h post infarction the larger isoform was not present (*Figure 37.b.)*. The larger TN-C isoform was observable 2 days after infarction, TN-C level increased at day 3 (day 0.5 and 1 vs. 3: **$p < 0.01$; day 3 vs. sham control: ***$p < 0.001$), and peaked 5 days post MI (day 0.5 and 1 vs. 5: ***$p < 0.001$; day 2 vs. 5: **$p < 0.01$). At this time point the larger isoform is 5-fold up-regulated compared to 2 days post infarction. After day 5 (day 5 vs. 10: **$p < 0.01$; day 5 vs. 14: *$p < 0.05$; day 5 vs. sham control: ***$p < 0.001$) and day 7 post infarction (day 7 vs. sham control: **$p < 0.01$; day 0.5 and 1 vs. 7: *$p < 0.05$) the large TN-C isoform was still present but level decreased. At day 10 and 14 post MI only marginal amounts of the large TN-C isoform were present.
In the sham control group from non-infarcted free wall samples of the left ventricle, no expression of the large TN-C isoform was detectable.

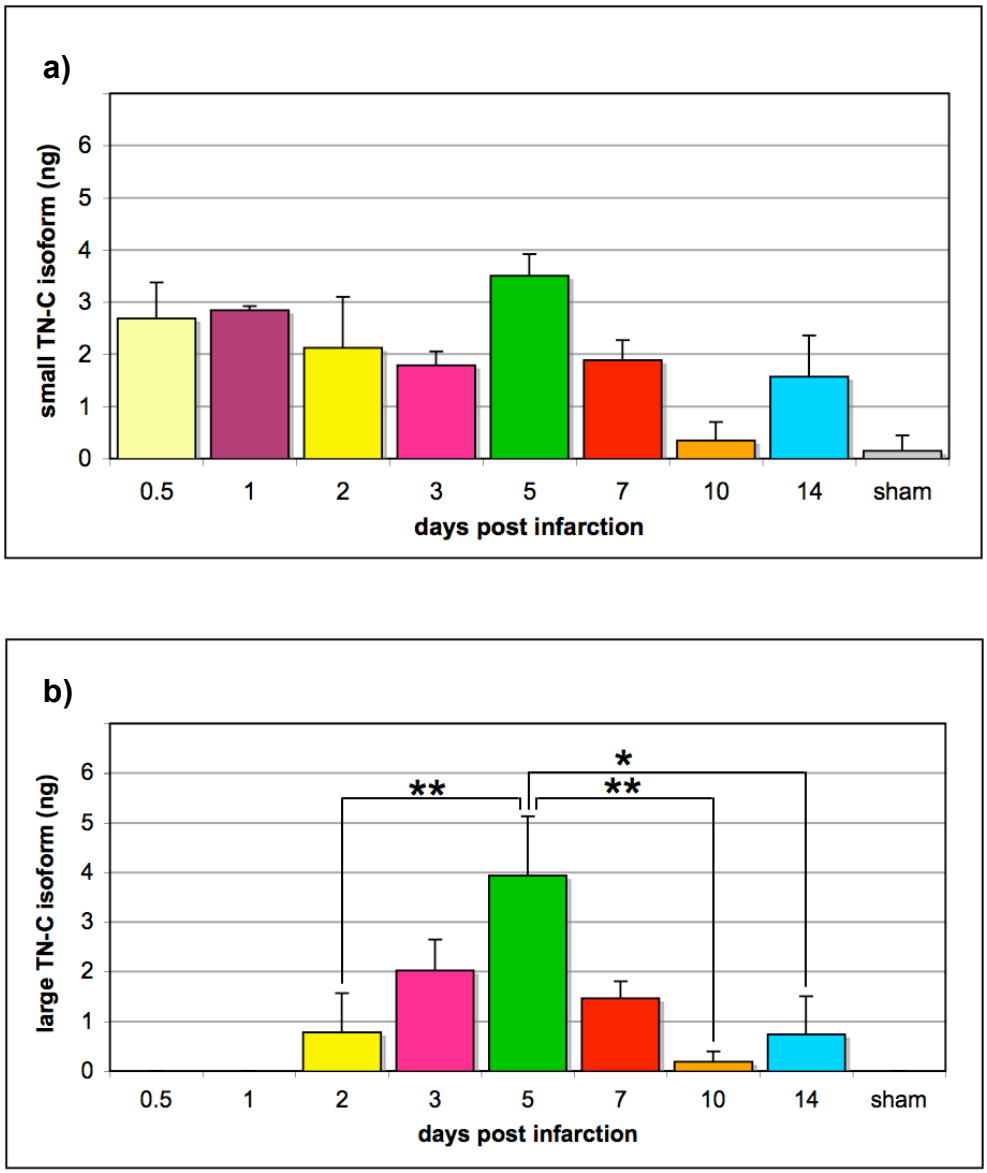

Figure 37. *Results from western blot analysis of* ***(a.)*** *small (p = ns), and* ***(b.)*** *large (**p < 0.01 and *p < 0.05) TN-C isoforms including groups of 0.5 to 14 days after myocardial infarction. Free wall tissue from the sham group was used as negative control. Details of results were described in the text.*

4. DISCUSSION

4.1. Sequencing Results

TN-C is a large hexameric molecule composed of multiple domains. Each domain binds to different cell surface receptors, including integrins and ECM components, such as fibronectin. Those interactions influence different cellular programs and functions. Isoforms differ in number of FN-III domains in the alternative spliced region. Small isoforms with no or only a few FN-III domains in the splicing region are often in association with embryonic development and organogenesis. In contrast, large isoforms are up-regulated under pathologic conditions [44].
So far human [116] and murine [117] TN-C cDNA and associated protein amino acid sequence were known. In this project rat cDNA sequence was analysed, encompassing an open reading frame of 6.057bp that encodes 2.019 amino acids with a calculated molecular weight of 222kDa.
In contrast, encoded human TN-C protein contains a total of 2.203 amino acids [116], whereas the murine protein sequence [117], similarly to the rat sequence, includes 2.019 amino acids.
Sequence identity in the alternative spliced FN-III domains varies a lot. In mouse tissues they share 52% of their nucleotide sequence on average. The lowest degree of similarity is recorded between FN-III domain A2 and D (41%), and the highest between domain A1 and A4 (80%) [118].

Four isoforms were detected and identified in the infarcted region after myocardial infarction. The largest of those isoforms include 5 FN-III domains in the alternative spliced region called A1, A2, A4, B, and D. Additionally isoforms with 2 (domain B and D), 1 (domain D), and none FN-III domains in the splicing region were identified (*Figure 16.).*
Especially those isoforms including FN-III domains B and/or D arise in a variety of different and multifaceted diseases.
In human invasive and pre-invasive breast disease mainly 2 isoforms were detected. Those variants included FN-III domain B and D, or only domain D [119]. Additionally,

a subset of ductal carcinoma in situ (DCIS) cases were also found to express these TN-C isoforms, which may be indicative of a high risk of invasion in these lesions.
Both TN-C variants, containing FN-III domains B and D, or only domain D, were also detected post infarction.
Furthermore, under pathologic conditions in a mouse model of habu snake venom (HSV) induced glomerulonephritis it was demonstrated that in particular, isoforms containing FN-III domain D are the major components of both healthy and pathological kidney. In contrast, domain C may not play an important role in the progress of HSV-induced glomerulonephritis [118].

However, the large isoform with 5 domains indicate a special role in myocardial remodelling, because large isoforms were associated with pathological conditions. To date FN-III domains AD1, AD2, and A3 have not been detected in the rat heart post MI.
From an evolutionary point of view, the availability of rodent TN-C domains equivalent to FN-III domains AD1 and AD2 is highly probable, because both domains were identified in human as well as in avian TN-C variants. These findings may suggest that both domains arose from duplication processes that occurred before the avian and mammalian species diverged. Therefore, both AD domains should be present in rodents as well. In contrast, the different FN-III A domains (A1, A2, A3, and A4) found in mammals presumably evolved later. In particular, domain A3 has only been detected in human TN-C and might be unique for primate TN-C variants [47]. Nevertheless further studies are required to analyse different TN-C domains, especially their binding interactions and functions.

Comparing fibronectin to TN-C it can be said that both consist of large disulfide-linked subunits composed of multiple structural domains and more than half of each molecule consists of FN-III domains, but the other domains differ a lot. Fibronectin is a dimeric molecule, whereas TN-C is a hexamer. Often both molecules are colocalised in tissues, but the occurrence of TN is much more restricted when compared with fibronectin [120].
Whereas fibronectin mediates mainly cell adhesion via destined integrins and proteoglycans, TN-C influences deadhesion of cells. One mechanism of TN-C to modulate cell adhesion is the blocking of cell attachment to fibronectin [57].

In human myocardial scars similar to TN-C, cardiac fibroblasts are the major source of fibronectin [67]. After injury fibronectin is present within 4 hours and increased at 48 hours. This early activation is thought to influence inflammatory, fibrotic and angiogenetic processes involved in wound healing. In mature myocardial scar tissue fibronectin is absent.

4.2. PCR Results

In tissue samples after myocardial infarction PCR analysis demonstrated a clear shift in TN-C isoform expression. Already 12 hours post infarction the small TN-C variant was slightly up-regulated (*Figure 17*.). The large variant, containing FN-III domains A1, A2, A4, B, and D (*Figure 16*.), peaked at day 3. Down-regulation started at day 7 after MI. In the sham control group only the small isoform was barely present (*Figure 17*.).

These results were in agreement with further studies, demonstrating a correlation with pathologic events and specific TN-C domains and isoforms [64, 118, 121]. Unfortunately, most studies determine this accordance in the field of tumour biology. Therefore, the detection of different spliced FN-III domains could be useful for assessment of invasiveness, tumour surveillance, as well as target structures for antibody based tumour detection and therapy [64, 119, 122, 123].

For instance, analysis of tissue samples from cutaneous squamous cell carcinoma and the precursor lesion actinic keratosis demonstrated that TN-C isoforms were specific up-regulated under pathologic conditions [122]. The large variant was present under both circumstances in comparison to normal skin samples, which were nearly negative for the large isoform.

However, the knowledge of up-regulated different TN-C isoforms in the failing heart could be a potent therapy approach.

4.3. Real Time-PCR Results

Real Time-PCR demonstrated a clear shift in TN-C expression after myocardial infarction. In the infarcted area 12h after infarction only a basis level of TN-C mRNA (*Figure 18.a.*) was present. Twenty-four hours after infarction TN-C level was slightly increased. Whereas a significant TN-C up-regulation was observable 2 days post MI that peaked at day 3 followed by a decrease at day 5. One week to 10 days post infarction mRNA level increased again and 14 days after MI TN-C protein level was comparable with basis level 12h after MI. In contrast to tissue from the infarcted region, tissue samples of free walls showed only barely mRNA appearance. Only 3 and 5 days post MI TN-C level slightly present (*Figure 18.b.*). From these results it can be concluded that TN-C plays an important role in the early phase of post myocardial infarction remodelling, and additionally, that TN-C protein expression is restricted to the infarcted region.

Studies from mouse central nervous system showed that TN-C isoform expression shifted in brain organogenesis [47]. TN-C expression peaked around P0 and decreased toward the second postnatal week. In adult brain tissue, only small isoforms persist. The signals obtained with the probes detecting FN-III domains A1 and A2 peaked at P0, whereas the signals for the domains C and D reached the maximal level at E16, suggesting that different TN-C variants might be expressed at different developmental stages.

4.4. Histological and Immunohistochemical Analysis

4.4.1. Morphometric Studies

Sudden induction of ischemia by occlusion of coronary arteries triggers a series of events including death of ischemic cardiomyocytes. Cardiomyocyte necrosis activates an inflammatory cascade that serves to clear the infarcted area of dead cells and matrix debris, resulting in rearrangement and healing of the damaged tissue within scar [124].

After MI heart structure and geometry are affected as well as composition of myocardial tissue components is impaired. Post infarction heart shows remarkable capacity to adapt to the new conditions of the left ventricle. After infarction a 2- to 3-fold increase in myocardial collagen above the normal level results in increased LV stiffness and mild dysfunction. Even a very small decrease in collagen below normal can lead to drastic consequences, including LV dilation, and rupture [30].

In this study only individuals with an infarct size of ≥ 20% of the left ventricle were included. Measured infarction size was similarly in all infarction groups (*Table 6.*). Left ventricular wall thinning was already detectable 5 days post MI (*Figure 19*. and *Figure 22.g., h.,* and *i.*). Furthermore 10 to 14 days after MI, thinning of the infarcted area was clearly observable (*Figure 19.* and *Figure 23.d.-i.).* Therefore, structure and geometry of the left ventricle was dramatically changed in comparison to the healthy sham control (*Figure 21.a., b.,* and *c.).*
It was reported that rearrangement of groups or bundles of myocytes results in decreased cell number across the ventricular wall [125]. This new organisation accounts for most wall thinning in the infarcted area and all thinning in non-infarcted regions. In non-infarcted regions, cell slippage accounts for all thinning. Cell stretch and loss of intercellular space are confined to the infarcted area and contribute less to wall thinning than does cell slippage.

4.4.2. TN-C and Trichrome (Goldner) Staining

A detailed descriptive analysis of the time course of TN-C deposition in healing myocardial infarcts is crucial to understand the role and function of this matricellular protein in cardiac healing after injury. Especially, the mechanisms responsible for TN-C induction in the infarcted area still remain unknown. Cytokines and growth factors, such as TNF-α, TGF-β, and bFGF, released in healing myocardial tissue stimulate fibroblast TN-C synthesis [126]. In addition, angiotensin II, an important regulator of cardiac remodelling and fibrous tissue deposition, is also known to influence TN-C expression [126]. The role of TN-C in infarct healing and remodelling remains unknown.

Results from this study are in agreement with further studies that demonstrated that during healing process after MI, TN-C protein and TN-C producing cells were found at the edges of the residual myocardium [85].
TN-C protein deposition appeared in the border zone within 12 hours after permanent coronary ligation (*Figure 24.b.* and *c.*). Seven days post infarction protein deposition peaked (*Figure 28.b., d.*, and *f.*) and down regulation started 10 days post MI (*Figure 30.b*. and *d.*). Two weeks post infarction TN-C protein expression was only slightly visible in the border zone between infarcted and non-infarcted region (*Figure 31.b*.). Seven days after infarction TN-C was present around healthy cardiomyocytes surrounded by infiltrated areas (*Figure 29.).*
Such transient up-regulation of TNC is consistent with the previous immunohistochemical findings for human infarcted myocardium [67]. In human healing myocardial scars TN-C was found 4-6 days post infarction and was located at the margin of the area of infarction. TN-C was present until 2-3 weeks after MI and 4 weeks post MI TN-C expression had disappeared completely.
This selectively expression in the border zone, between infarcted and non-infarcted areas suggests that it may be important in the dynamic events associated with cardiac remodelling following myocardial injury.

TN-C may not only modulate attachment of cardiomyocyte on the ECM, but may also play multiple roles in myocardial tissue remodelling to control interstitial cell behaviour during repair of tissue damage [85].
As reported before, TN-C is synthesised during the acute and early phase after infarction by interstitial cells in the border zone [85]. This early expression of TN-C after tissue injury is related to cell migration and proliferation. Therefore it can be concluded that TN-C act as a de-adhesive adapter molecule. TN-C may loosen the strong adhesion of surviving cardiomyocytes to connective tissue and thereby facilitate tissue reorganisation. TN-C expression virtually disappears in the mature scar tissue.
In addition, a recent study examined the effects of TN-C deficiency in a model of electrical cardiac injury [92]. It was demonstrated that TN-C null mice exhibit delayed recruitment of myofibroblasts in the injured myocardial site indicating that TN-C promotes recruitment of myofibroblasts in the early stages of myocardial repair by stimulating cell migration and as well cell differentiation.

Furthermore, the myocardial collagen meshwork is damaged after myocardial injury. The extent of collagen damage correlates with the degree of infarct expansion [127]. Post infarction several endogenous molecules that affect collagen synthesis are up-regulated. Those molecules include bradykinin, TNF-α, IL-1, INF-γ, and several agents that are used therapeutically, affect collagen turnover and be considered as anti-fibrotic [30]. After infarction collagen molecules were newly synthesised and embedded in scar tissue. This can potentially alter ECM remodelling in the infarcted region and impair the healing process [30].
The major cardiac fibrillar collagens are types I and III. In the human heart 85% of total collagen is type I, which is associated mainly with thick fibres that confer tensile strength and resistance to stretch and deformation. In contrast, only about 11% of total collagen is type III, which is associated with thin fibres that confer resilience. The synthesis of collagens is slow compared to non-collagen proteins and the 80- to 120-day half-life of collagen is 10 times longer than that for non-collagen proteins. Therefore, replacement of collagen fibres after degradation of ECM components occurs very slowly. This long time frame includes the potential vulnerability for harmful remodelling events in conditions associated with increased ECM degradation such as acute MI [30].

In this study, Trichrome (Goldner) staining showed an overview of collagen fibre accumulation in the centre of the forming scar until day 2 post infarction. Five days after MI collagen formation was observed in the infarcted area and in the border zone. Collagen fibres were degraded and new fibres were synthesised to strengthen the forming scar tissue after injury. This controlled and regulated degradation of ECM components post MI is a critical step for growth, remodelling, rearrangement, repair, and healing processes. This events are mainly regulated by MMPs and their counterparts the TIMPs [30].

4.4.3. TN-C Staining of Control Organs

As well as in myocardial tissue, TN-C is up-regulated under pathologic conditions in other tissues. Vascular smooth muscle cells and endothelial cells of various organs have the potential to synthesise TN-C. It was demonstrated for a diversity of

pathologies such as MI [91] or CHC [107] that serum TN-C levels were increased. Those high levels of circulating TN-C may influence other organs.
Furthermore, elevated levels of circulating inflammatory mediators in heart failure might also stimulate endothelial cells of, for example, the liver, to secrete TN-C into the blood stream [98].

In this study TN-C protein deposit was analysed in kidney, liver, lung, and spleen tissues 7 days post infarction and compared to the sham control group (*Figure 33.-36.*). An increased TN-C level was observed only in kidney and liver tissues post infarction (*Figure 33.* and *34.*). Further studies are needed to demonstrate if TN-C expression was up-regulated after MI in liver and kidney tissues or if circulating TN-C accumulates in those organs.

Studies showed that TN-C is involved in liver fibrosis in CHC patients [128]. Large variants were not expressed in normal liver tissue, but were up-regulated in CHC, especially at sites of interface hepatitis and confluent necrosis, TN-C and its variants are produced by hepatic stellate cells (HSCs)/myofibroblasts.
TN-C staining in normal liver samples is positive with the 4F10TT antibody recognising the EGF-L repeats of all TN-C variants, which was used as well in this study. In contrast, normal liver samples are negative for the TN-C antibody 6C6MS, which recognise the FN-III domain C included in the large TN-C isoform. Liver samples from patients with CHC are positive for both antibodies. Additional serum TN-C is a useful marker of the activity of CHC, in particular of the degree of piecemeal necrosis [107].

Normal tissue samples from rat lungs (*Figure 35.a.)* are barely positive for TN-C staining [129]. Whereas, TN-C expression increased during pulmonary injury induced by intratracheal bleomycin instillation. After initial lung injury TN-C was primarily present during the early inflammatory phase [129] .

Within spleen tissue TN-C was found to be an ECM component at all developmental ages as well as in adults. Especially, ring fibres, which are modified basement membranes around venous sinuses, were positive for TN-C [130].

In kidneys from adult mice, no TN-C can be found in the cortex, but interspersed patches of staining are visible in the medullary stroma [131]. In a mouse model of HSV induced glomerulonephritis it was shown that TN-C was up-regulated under pathologic conditions in the kidney [118].

4.5. Western Blot Results

Western blot analysis showed a clear shift in TN-C isoform expression. As known, larger TN-C isoforms are prominent under pathologic conditions where remodelling occur. So it is not surprising, that larger isoforms were up-regulated in the infarcted region.
Similar results were obtained in other tissues, such as kidneys. After glomerulonephritis 2 isoforms were up-regulated in kidney after injury [118].

In myocardial tissue the small TN-C isoform was present within 12 hours and showed no significant change until 2 weeks post MI compared to the sham control group (*Figure 37.a.*).
In contrast, 12 to 24 hours after infarction the large isoform were not existent in scar tissue (*Figure 37.b.*). Large TN-C isoform up-regulation started at day 2 post MI and peaked at day 5. After day 5 post infarction large TN-C isoform level decreased and protein was only marginal present 2 weeks after infarction.
TN-C fragments smaller than 230kDa were presumably degraded molecules [105]. TN-C and members of the MMP family, which play an important role in TN-C degradation, are reciprocal regulated. TN-C influences expression and activity of MMPs, leading to a changed composition of the preexisting ECM. This altered tissue microenvironment influences cellular adhesion, cell motility, growth, survival, and/or differentiation [5].

From this results can be concluded, that larger isoforms play an important, even if not totally understood, role in the first phase of remodelling post infarction. Even if western blot analysis not allowed detailed separation of all single TN-C isoforms a clear shift was observable and gives a clue that TN-C plays in the dynamic process of cardiac remodelling an important role.

4.6. Knockout Mice

Knockout mice are important animal models to study the specific gene inactivation and give a clue for role and function of turned off proteins. Until now, TN-C [93], TN-R [132] and TN-X [133] deficient mice have been generated. Interestingly, TN-X null mice show similar symptoms as in the human Ehlers-Danlos syndrome, confirming a causative role for this gene in this disease [36].
Additionally, double knockouts lacking TN-C/TN-X [134] and TN-C/TN-R [135] have been generated.
TN-C knockout mice, generated in 1992 have no demonstrative phenotypic defects [93]. They were born alive, were fertile but their behaviour was markedly abnormal [136]. Mice showed hyper locomotion, stereotyped turning behaviour, and poor swimming ability resulting from altered levels of neurotransmission in brain chemistry [137]. This abnormal behaviour and movements of TN knockout mice is similar to Rett's syndrome.

Healing of cutaneous wounds in TN-C deficient mice was analysed [138]. Skin wounds only showed a diminished fibronectin expression in those mice. Surprisingly, the reduced amount of fibronectin has no influence on the quality of the healing process. These findings would be interesting in combination with healing of myocardial scars after myocardial infarction. Therefore, it would be interesting to check the role of TN-C in the healing scar post MI in TN-C knockout mice.

Furthermore the role of two other members of the matricellular protein family, OPN [139] and TSP2 [140] has been investigated after infarction in their respective null mice. The OPN as well as the TSP2 deficient mice showed a clear phenotype after MI. The OPN null mice had an exaggerated left ventricle dilatation, whereas more than 90% of the TSP2 null mice died after infarction due to cardiac rupture.
These data demonstrate that both matricellular proteins are necessary to maintain a normal cardiac structure and function after myocardial injury.

The relatively mild developmental phenotypes described in TN-C knockout mice [93] might be explained by functional redundancy within the TN family but, as yet, there is no evidence that the expression pattern of one TN changes in response to the

knockout of another TN molecule [40].
Potential candidates for this compensatory effect are other members of the TN family, although the expression patterns of identified members of this family show only partial overlap [40, 132]. For example the compensatory effect of TN-X and TN-C in skin tissue [141].
This leaves open the possibility that an uncharacterised TN could be present in the ECM and assume this role [40].

4.7. Tenascin-C - A Potential New Biomarker?

Searching for new biomarkers, which are more sensitive and specific a lot of candidates were found. Promising potent markers for MI and acute cardiac diseases may be sCD40, myeloperoxidase, ischemia-modified albumin, pregnancy-associated plasma protein-A, choline, placental growth factor, cystatin C and fatty acid binding protein [78].
In this context it was reported previously, that serum TN-C might also be a novel biomarker for myocardial injury and the remodelling process post acute MI [91]. For instance, patients with IDC showed a significant higher serum TN-C level compared to the control group. Additionally, patients with terminal heart failure showed a significant elevated TN-C serum level [142]. Those elevated TN-C levels were significantly associated with the New York Heart Association (NYHA) functional class, left ventricular ejection fraction (EF), left ventricular end-systolic diameter and BNP level. Moreover, a positive correlation between TN-C level and troponin T level was shown, indicating that circulating TN-C is generally associated with the severity of left ventricular dysfunction [97].

Most reports show an association with TN-C expression and tumour development. In various types of carcinomas TN-C expression correlates with angiogenesis and local infiltration [99].
Even those available studies often do not distinguish between the many different TN-C splicing variants that exist. However, only some studies show that certain isoforms may be more frequent under specific pathologic conditions than in normal and healthy tissues [123]. Thus, a detailed distinction between TN-C splice variants and

description of different FN-III domains in the alternative spliced region may enable a more precise interpretation.

It was shown that tumour-targeting antibodies against the alternative spliced FN-III domains A1 and D of the large TN-C isoform, which accumulates at tumour rich sites, are promising building blocks for the development of antibody-based pharmaceuticals [100].
For radio-immunotherapy in patients with newly diagnosed malignant tumours β-particle-emitting ^{131}I-labeld anti-TN-C antibodies were used in a phase-II trail showing promising results [101, 143]. In another study α-emitting ^{211}At-labeld anti-TN-C antibodies were used for regional targeted radiotherapy, showing anti-tumour benefits in patients with malignant central nervous system tumours [144].

Taken together, TN-C is a very useful marker for the early phases of connective tissue remodelling associated with many pathologies, such as tumour development or MI. An early inflammatory response is in the majority of cases associated with enhanced TN-C levels, both in the tissue and in plasma.
However, since some highly malignant tumours seem to lose TN-C expression during progression, caution is required to use TN-C as a marker for diagnosis. Nevertheless, in certain instances this molecule has proven its value as a convenient diagnostic tool and perhaps even for the treatment of cancer.
However, to reach the full diagnostic and therapeutic potential, more basic research is needed to clarify the precise function and gene regulation of TN-C.

4.8. Limitations of the Study

The remodelling process post infarction is very dynamic and only eight time points after infarction were included in this study to provide an insight into this event. Those selected time points represents just snap shots in this process.
The small sample size is another study limitation.

5. CONCLUSION

Taken together, small TN-C isoforms, with few or none FN-III domains in the alternative spliced region, are in association with the normal and healthy ECM. In contrast, large TN-C isoforms are up-regulated in many tissues under pathologic conditions.

After sequencing the complete rat TN-C cDNA, four different TN-C isoforms were identified, which are present in the heart after myocardial infarction. Those isoforms differ in size because of alternative splicing processes within the fibronectin-III (FN-III) domain.
Arising isoforms include 5, 2, 1, and none FN-III domains in the alternative spliced region. Interestingly, the large TN-C isoform was only present very short in the early remodelling phase post infarction.

This study demonstrates a time dependent TN-C up-regulation post myocardial infarction and, additionally, a shift in TN-C isoform expression post MI. This time dependent shift in TN-C isoform expression indicates a special role for FN-III domains.
Further experimental studies are necessary to show precise function of distinct domains in different spliced TN-C variants. So TN-C may serve as a useful biomarker in cardiovascular diseases.

6. REFERENCES

1. Bornstein P and Sage H E, *Matricellular proteins: extracellular modulators of cell function.* Curr Opin Cell Biol, 2002. **14**(5): p. 608-616.
2. Murphy-Ullrich J E, *The de-adhesive activity of matricellular proteins: is intermediate cell adhesion an adaptive state?* J Clin Invest, 2001. **107**(7): p. 785-790.
3. Schellings M W M, Pinto Y M and Heymans S, *Matricellular proteins in the heart: possible role during stress and remodeling.* Cardiovasc Res, 2004. **64**(1): p. 24-31.
4. Henry H C and Schwarzbauer J E, *Meet the Tenascins: Multifunctional and Mysterious.* J Biol Chem, 2005. **280**(29): p. 26641-26644.
5. Jones F S and Jones P L, *The tenascin family of ECM glycoproteins: structure, function, and regulation during embryonic development and tissue remodeling.* Dev Dyn, 2000. **218**(2): p. 235-259.
6. Chiquet-Ehrismann R, Mackie E J, Pearson C A and Sakakura T, *Tenascin: an extracellular matrix protein involved in tissue interactions during fetal development and oncogenesis.* Cell, 1986. **47**(1): p. 131-139.
7. Mackie E J, *Molecules in focus: tenascin-C.* Int J Biochem & Cell Biol, 1997. **29**(10): p. 1133-1137.
8. Bourdon M A, Wikstrand C J, Furthmayr H, Matthews T J, et al., *Human glioma-mesenchymal extracellular matrix antigen defined by monoclonal antibody.* Cancer Res, 1983. **43**(6): p. 2796-2805.
9. Chiquet M and Fambrough D, *Chick myotendinous antigen. I. A monoclonal antibody as a marker for tendon and muscle morphogenesis.* J Cell Biol, 1984. **98**(6): p. 1937-1946.
10. Chiquet M and Fambrough D M, *Chick myotendinous antigen. II. A novel extracellular glycoprotein complex consisting of large disulfide-linked subunits.* J Cell Biol, 1984. **98**(6): p. 1937-1946.
11. Erickson H P and Inglesias J L, *A six-armed oligomer isolated from cell surface fibronectin preparations.* Nature, 1984. **311**(5983): p. 267-269.
12. Grumet M, Hoffman S, Crossin K L and Edelman G M, *Cytotactin, an extracellular matrix protein of neural and non-neural tissues that mediates glia-neuron interaction.* Proc Natl Acad Sci U S A, 1985. **82**(23): p. 8075-8079.

13. Kruse J, Keilhauer G, Faissner A, Timpl R, et al., *The J1 glycoprotein - a novel nervous system cell adhesion molecule of the L2/HNK-1 family.* Nature, 1985. **316**(6024): p. 146-148.
14. Rettig W J and Garin-Chesa P, *Cell type-specific control of human neuronectin secretion by polypeptide mediators and phorbol ester.* J Histochem Cytochem, 1989. **37**(12): p. 1777-1786.
15. Erickson H E and Taylor H C, *Hexabrachion proteins in embryonic chicken tissues and human tumors.* J Cell Biol, 1987. **105**(3): p. 1387-1394.
16. Hoffman S, Crossin K L and Edelman G M, *Molecular forms, binding functions, and developmental expression patterns of cytotactin and cytotactin-binding proteoglycan, an interactive pair of extracellular matrix molecules.* J Cell Biol, 1988. **106**(2): p. 519-532.
17. Aufderheide E and Ekblom P, *Tenascin during gut development: Appearance in the mesenchyme, shift in molecular forms, and dependence on epithelial-mesenchymal interactions.* J Cell Biol, 1988. **107**(6): p. 2341-2349.
18. Järvinen T A H, Kannus P, Järvinen T L N, Jozsa L, et al., *Tenascin-C in the pathobiology and healing process of musculoskeletal tissue injury.* Scand J Med Sci Sports, 2000. **10**(6): p. 376-382.
19. Gullberg D, Velling T, Sjöberg G, Salmivirta K, et al., *Tenascin-C expression correlates with macrophage invasion in Duchenne muscular dystrophy and in myositis* Neuromuscul Disord, 1997. **7**(1): p. 39-54.
20. Rettig W J, Erickson H P, Albino A P and Garin-Chesa P, *Induction of human tenascin (neuronectin) by growth factors and cytokines: cell type-specific signals and signalling pathways.* J Cell Sci, 1994. **107**(2): p. 487-497.
21. LaFleur D W, Fagin J A, Forrester J S, RubinO S A, et al., *Cloning and Characterization of Alternatively Spliced Isoforms of Rat Tenascin: Platelet-derived growth factor-BB markedly stimulates expression of spliced variants of tenascin mRNA in arterial smooth muscle cells.* J Biol Chem, 1994. **269**(32): p. 20757-20763.
22. Orend G and Chiquet-Ehrismann R, *Tenascin-C induced signaling in cancer.* Cancer Lett, 2006. **244**(2): p. 143-163.
23. Jinnin M, Ihn H, Asano Y, Yamane K, et al., *Tenascin-C upregulation by transforming growth factor-in human dermal fibroblasts involves Smad3, Sp1, and Ets1.* Oncogene, 2004. **23**(9): p. 1656-1667.

24. Ihida-Stansbury K, McKean D M, Lane K B, Loyd J E, et al., *Tenascin-C is induced by mutated BMP type II receptors in familial forms of pulmonary arterial hypertension.* Am J Physiol Lung Cell Mol Physiol, 2006. **291**(4): p. 694-702.
25. Alford A I and Hankenson K D, *Matricellular proteins: Extracellular modulators of bone development, remodeling, and regeneration.* Bone, 2006. **38**(6): p. 749-757.
26. Spinale F G, *Myocardial matrix remodeling and the matrix metalloproteinases: influence on cardiac form and function.* Physiol Rev, 2007. **87**(4): p. 1285-1342.
27. Galoian K A, Garamszegi N, Garamszegi S P and Scully S P, *Molecular mechanism of tenascin-C action on matrix metalloproteinase-1 invasive potential.* Exp Biol Med, 2007. **232**: p. 515-522.
28. Siri A, Knäuper V, Veirana N, Caocci F, et al., *Different susceptibility of small and large human tenascin-C isoforms to degradation by matrix metalloproteinases.* J Biol Chem, 1995. **270**(15): p. 8650-8654.
29. Bell S C, Pringle J H, Taylor D J and Malak T M, *Alternatively spliced tenascin-C mRNA isoforms in human fetal membranes.* Mol Hum Reprod, 1999. **5**(11): p. 1066-1076.
30. Jugdutt B I, *Ventricular remodeling after infarction and the extracellular collagen matrix: When is enough enough?* Circulation, 2003. **108**(11): p. 1395-1403.
31. Joester A and Faissner A, *The structure and function of tenascins in the nervous system.* Matrix Biol, 2001. **20**: p. 13-22.
32. Bristow J, Tee M K, Gitelman S E, Mellon S H, et al., *Tenascin-X: a novel extracellular matrix protein encoded by the human XB gene overlapping P450c21B.* J Cell Biol, 1993. **122**(1): p. 265-278.
33. Burch G H, Gong Y, Liu W, Dettman R W, et al., *Tenascin-X deficiency is associated with Ehlers-Danlos syndrome.* Nat Genet, 1997. **17**(1): p. 104-108.
34. Matsumoto K, Saga Y, Ikemura T, Sakakura T, et al., *The distribution of tenascin-X is distinct and often reciprocal to that of tenascin-C.* J Cell Biol, 1994. **125**(2): p. 483-493.
35. Chiquet-Ehrismann R and Chiquet M, *Tenascins: regulation and putative functions during pathological stress.* J Pathol, 2003. **200**(4): p. 488-499.

36. Bristow J, Carey W, Egging D and Schalkwijk J, *Tenascin-X, collagen, elastin, and the Ehlers-Danlos syndrome.* Am J Med Genet, 2005. **139**(1): p. 24-30.
37. Hagios C, Brown-Luedi M and Chiquet-Ehrismann R, *Tenascin-Y, a component of distinctive connective tissues, supports muscle cell growth.* Exp Cell Res, 1999. **253**(2): p. 607-617.
38. Hagios C, Koch M, Spring J, Chiquet M, et al., *Tenascin-Y: a protein of novel domain structure is secreted by differentiated fibroblasts of muscle connective tissue.* J Cell Biol, 1996. **134**(6): p. 1499-1512.
39. Weber P, Montag D, Schachner M and Bernhardt R R, *Zebrafish tenascin-W, a new member of the tenascin family.* J Neurobiol, 1998. **35**(1): p. 1-16.
40. Scherberich A, Tucker R P, Samandari E, Brown-Luedi M, et al., *Murine tenascin-W: a novel mammalian tenascin expressed in kidney and at sites of bone and smooth muscle development.* J Cell Sci, 2004. **117**(4): p. 571-581.
41. Siri A, Carnemolla B, Saginati M, Leprini A, et al., *Human tenascin: primary structure, pre-mRNA splicing patterns and localization of the epitopes recognized by two monoclonal antibodies* Nucleic Acids Res, 1991. **19**(3): p. 525-531.
42. Oberhauser A F, Marszalek P E, Erickson H P and Fernandez J M, *The molecular elasticity of the extracellular matrixprotein tenascin.* Nature, 1998. **393**: p. 181-185.
43. Kammerer R A, Schulthess T, Landwehr R, Lustig A, et al., *Tenascin-C Hexabrachion Assembly Is a Sequential Two-step Process Initiated by Coiled-coil -Helices.* J Biol Chem, 1998. **273**(17): p. 10602-10608.
44. Jones P L and Jones F S, *Tenascin-C in development and disease: gene regulation and cell function.* Matrix Biol, 2000. **19**(7): p. 581-596.
45. Borsi L, Allemanni G, Gaggero B and Zardi L, *Extracellular pH controls pre-mRNA alternative splicing of tenascin-C in normal, but not in malignantly transformed, cells.* Int J Cancer, 1998. **66**(5): p. 632-635.
46. Zhao Y and Young S L, *TGF-beta regulates expression of tenascin alternative-splicing isoforms in fetal rat lung.* Am J Physiol Lung Cell Mol Physiol, 1995. **268**(2): p. 173-180.
47. Joester A and Faissner A, *Evidence for Combinatorial Variability of Tenascin-C Isoforms and Developmental Regulation in the Mouse Central Nervous System.* Biol Chem, 1999. **274**(24): p. 17144-17151.

48. Tucker R P, Hammarback J A, Jenrath D A, Mackie E J, et al., *Tenascin expression in the mouse: in situ localization and induction in vitro by bFGF.* J Cell Sci, 1993. **104**(1): p. 69-76.

49. Fischer D, Brown-Lüdi M, Schulthess T and Chiquet-Ehrismann R, *Concerted action of tenascin-C domains in cell adhesion, anti-adhesion and promotion of neurite outgrowth.* J Cell Sci, 1997. **110**(13): p. 1513-1522.

50. Prieto A L, Jones F S, Cunningham B A, Crossin K L, et al., *Localization during development of alternatively spliced forms of cytotactin mRNA by in situ hybridization.* J Cell Biol, 1990. **111**(2): p. 685-698.

51. Kaplony A, Zimmermann D R, Fischer R W, Imhof B A, et al., *Tenascin Mr 220,000 isoform expression correlates with corneal cell migration.* Development, 1991. **112**(2): p. 605-614.

52. Borsi L, Carnemolla B, Nicolò G, Spina B, et al., *Expression of different tenascin isoforms in normal, hyperplastic and neoplastic human breast tissues.* Int J Cancer, 1992. **52**(5): p. 688-692.

53. Trebaul A, Chan E K and Midwood K S, *Regulation of fibroblast migration by tenascin-C.* Biochem Soc Trans, 2007. **35**(4): p. 695-697.

54. Bourdon M A and Ruoslahti E, *Tenascin Mediates Cell Attachment through an RGD-dependent Receptor.* J Cell Biol, 1989. **108**: p. 1149-1155.

55. Murphy-Ullrich J E, Lightner V A, Aukhil I, Yan Y Z, et al., *Focal adhesion integrity is downregulated by the alternatively spliced domain of human tenascin.* J Cell Biol, 1991. **115**(4): p. 1127-1136.

56. Chiquet-Ehrismann R, Matsuoka Y, Hofer U, Spring J, et al., *Tenascin variants: differential binding to fibronectin and distinct distribution in cell cultures and tissues.* Cell Regulation, 1991. **2**: p. 927-938.

57. Huang W, Chiquet-Ehrismann R, Moyano J V, Garcia-Pardo A, et al., *Interference of tenascin-C with syndecan-4 binding to fibronectin blocks cell adhesion and stimulates tumor cell proliferation.* Cancer Res, 2001. **61**: p. 8586-8594.

58. Götz B, Scholze A, Clement A, Joester A, et al., *Tenascin-C contains distinct adhesive, anti-adhesive, and neurite outgrowth promoting sites for neurons* J Cell Biol, 1996. **132**(4): p. 681-699.

59. Wallner K, Shah P K and Sharifi B G, *Balloon catheterization induces arterial expression of new Tenascin-C isoform.* Atherosclerosis, 2002. **161**(1): p. 75-83.

60. Sriramarao P and Bourdon M A, *A novel tenascin type III repeat is part of a complex of tenascin mRNA alternative splices.* Nucleic Acids Res, 1993. **21**(1): p. 163-168.

61. Mighell A J, Thompson J, Hume W J, Markham A F, et al., *Human tenascin-C: identification of a novel type III repeat in oral cancer and of novel splice variants in normal, malignant and reactive oral mucosae.* Int J Cancer, 1997. **72**(2): p. 236-240.

62. Tucker R P, Spring J, Baumgartner S, Martin D, et al., *Novel tenascin variants with a distinctive pattern of expression in the avian embryo.* Development, 1994. **120**(3): p. 637-647.

63. Hanamura N, Yoshida T, Matsumoto E, Kawarada Y, et al., *Expression of fibronectin and tenascin-C mRNA by myofibroblasts, vascular cells and epithelial cells in human colon adenomas and carcinomas.* Int J Cancer, 1997. **73**(1): p. 10-15.

64. Berndt A, Anger K, Richter P, Borsi L, et al., *Differential expression of tenascin-C splicing domains in urothelial carcinomas of the urinary bladder.* J Cancer Res Clin Oncol, 2006. **132**(8): p. 537-546.

65. Franz M, Hansen T, Borsi L, Geier C, et al., *A quantitative co-localization analysis of large unspliced tenascin-CL and laminin-5/c2-chain in basement membranes of oral squamous cell carcinoma by confocal laser scanning microscopy.* J Oral Pathol Med, 2007. **36**(1): p. 6-11.

66. Dueck M, Riedl S, Hinz U, Tandara A, et al., *Detection of tenascin-C isoforms in colorectal mucosa, ulcerative colitis, carcinomas and liver metastases.* Int J Cancer, 1999. **82**(4): p. 477-483.

67. Willems I E, Arends J W and Daemen M J, *Tenascin and fibronectin expression in healing human myocardial scars.* J Pathol, 1996. **179**(3): p. 321-325.

68. Mackie E J, Halfter W and Liverani D, *Induction of tenascin in healing wounds.* J Cell Biol, 1988. **107**(6): p. 2757-2767.

69. Latijnhouwers M A, de Jongh G J, Bergers M, de Rooij M J, et al., *Expression of tenascin-C splice variants by human skin cells.* Arch Dermatol Res, 2000. **292**(9): p. 446-454.

70. Filenius S, Tervo T and Virtanen I, *Production of fibronectin and tenascin isoforms and their role in the adhesion of human immortalized corneal epithelial cells.* Invest Ophthalmol Vis Sci, 2003. **44**(8): p. 3317-3325.

71. Thygesen K, Alpert J S and White H D, *Universal definition of myocardial infarction.* Circulation, 2007. **116**(22): p. 2634-2653.

72. Anand S S, Islam S, Rosengren A, Franzosi M G, et al., *Risk factors for myocardial infarction in women and men: insights from the INTERHEART study.* Eur Heart J, 2008. **29**(7): p. 932-940.

73. Goldthwaite C A, *Mending a broken heart: stem cells and cardiac repair.* Regenerative Medicine, 2006(6).

74. Dobaczewski M, Bujak M, Zymek P, Ren G, et al., *Extracellular matrix remodeling in canine and mouse myocardial infarcts.* Cell Tissue Res, 2006. **324**(3): p. 475-488.

75. Morrow D A and de Lemos J A, *Benchmarks for the assessment of novel cardiovascular biomarkers.* Circulation, 2007. **115**(8): p. 949-952.

76. Adams III J E, *Clinical application of markers of cardiac injury: basic concepts and new considerations.* Clin Chimica, 1999. **284**: p. 127-134.

77. Karras D J and Kane D L, *Serum markers in the emergency department diagnosis of acute myocardial infarction.* Emerg Med Clin North Am, 2001. **19**(2): p. 321-337.

78. Jaffe A S, Babuin L and Apple F S, *Biomarkers in acute cardiac disease.* J Am Coll Cardiol, 2006. **48**(1): p. 1-11.

79. Braunwald E, *Biomarkers in heart failure.* N Engl J Med, 2008. **358**(20): p. 2148-2159.

80. Mueller C, Mueller B and Perruchoud A P, *Biomarkers: past, present, and future.* Swiss Med WKLY, 2008. **138**(15-16): p. 225-229.

81. Alpert J S, Malasky B R and Thygesen K, *Redefining myocardial infarction for the 21st century.* Trans Am Clin Climatol Assoc, 2004. **115**: p. 79-94.

82. Warburton F G, Allan E, Laing G S and Waddecar J, *Increased Lactate Dehydrogenase 3 in Serum after Myocardial Infarction.* Nature, 1967. **215**: p. 287-289.

83. Sato I and Shimada K, *Quantitative analysis of tenascin in chordae tendineae of human left ventricular papillary muscle with aging.* Ann Anat, 2001. **183**(5): p. 443-448.

84. Imanaka-Yoshida K, Hiroe M, Yasutomi Y, Toyozaki T, et al., *Tenascin-C is a useful marker for disease activity in myocarditis.* J Pathol, 2002. **197**(3): p. 388-394.

85. Imanaka-Yoshida K, Hiroe M, Nishikawa T, Ishiyama S, et al., *Tenascin-C modulates adhesion of cardiomyocytes to extracellular matrix during tissue remodeling after myocardial infarction.* Lab Invest, 2001. **81**(7): p. 1015-1024.

86. Imanaka-Yoshida K, Knudsen K A and Linask K K, *N-cadherin is required for the differentiation and initial myofibrillogenesis of chick cardiomyocytes.* Cell Motil Cytoskeleton, 1998. **39**(1): p. 52-62.

87. Linask K K and Lash J W, *Early heart development: dynamics of endocardial cell sorting suggests a common origin with cardiomyocytes.* Dev Dyn, 1993. **196**(1): p. 62-69.

88. Imanaka-Yoshida K, Matsumoto K, Hara M, Sakakura T, et al., *The dynamic expression of tenascin-C and tenascin-X during early heart development in the mouse.* Differentiation, 2003. **71**(4-5): p. 291-298.

89. Tremble P, Chiquet-Ehrismann R and Werb Z, *The extracellular matrix ligands fibronectin and tenascin collaborate in regulating collagenase gene expression in fibroblasts.* Mol Biol Cell, 1994. **5**: p. 439-453.

90. Ducharme A, Frantz S, Aikawa M, Rabkin E, et al., *Targeted deletion of matrix metalloproteinase-9 attenuates left ventricular enlargement and collagen accumulation after experimental myocardial infarction.* J Clin Invest, 2000. **106**(1): p. 55-62.

91. Sato A, Aonuma K, Imanaka-Yoshida K, Yoshida T, et al., *Serum tenascin-C might be a novel predictor of left ventricular remodeling and prognosis after acute myocardial infarction.* J Am Coll Cardiol, 2006. **47**(11): p. 2319-2325.

92. Tamaoki M, Imanaka-Yoshida K, Yokoyama K, Nishioka T, et al., *Tenascin-C regulates recruitment of myofibroblasts during tissue repair after myocardial injury.* Am J Pathol, 2005. **167**(1): p. 71-78.

93. Saga Y, Yagi T, Ikawa Y, Sakakura T, et al., *Mice develop normally without tenascin.* Genes Dev, 1992. **6**(10): p. 1821-1831.

94. Morimoto S, Imanaka-Yoshida K, Hiramitsu S, Kato S, et al., *Diagnostic utility of tenascin-C for evaluation of the activity of human acute myocarditis.* J Pathol, 2005. **205**(4): p. 460-467.

95. Frangogiannis N G, Shimoni S, Chang S M, Ren G, et al., *Active interstitial remodeling: An important process in the hibernating human myocardium.* J Am Coll Cardiol, 2002. **39**(9): p. 1468-1474.

96. Tamura A, Kusachi S, Nogami K, Yamanishi A, et al., *Tenascin expression in endomyocardial biopsy specimens in patients with dilated cardiomyopathy: distribution along margin of fibrotic lesions.* Heart, 1996. **75**(3): p. 291-294.

97. Aso N, Tamura A and Nasu M, *Circulating tenascin-C levels in patients with idiopathic dilated cardiomyopathy.* Am J Cardiol, 2004. **94**(11): p. 1468-1470.

98. Terasaki F, Okamoto H, Onishi K, Sato A, et al., *Higher serum tenascin-C levels reflect the severity of heart failure, left ventricular dysfunction and remodeling in patients with dilated cardiomyopathy.* Circ J, 2007. **71**: p. 327-330.

99. Chiquet-Ehrismann R, *Molecules in focus - Tenascins.* Int J Biochem & Cell Biol, 2004. **36**(6): p. 986-990.

100. Brack S S, Silacci M, Birchler M and Neri D, *Tumor-targeting properties of novel antibodies specific to the large isoform of tenascin-C.* Clin Cancer Res, 2006. **12**(10): p. 3200-3208.

101. Reardon D A, Akabani G, Coleman R E, Friedman A H, et al., *Phase II trial of murine (131)I-labeled antitenascin monoclonal antibody 81C6 administered into surgically created resection cavities of patients with newly diagnosed malignant gliomas.* J Clin Oncol, 2002. **20**(5): p. 1389-1397.

102. Brown M T, Coleman R E, Friedman A H, Friedman H S, et al., *Intrathecal 131I-labeled antitenascin monoclonal antibody 81C6 treatment of patients with leptomeningeal neoplasms or primary brain tumor resection cavities with subarachnoid communication: phase I trial results.* Clin Cancer Res, 1996. **2**(6): p. 963-972.

103. Bigner D D, Brown M, Coleman E R, Friedman A H, et al., *Phase I studies of treatment of malignant gliomas and neoplastic meningitis with131I-radiolabeled monoclonal antibodies anti-tenascin 81C6 and anti-chondroitin proteoglycan sulfate Me1-14 F (ab') 2-a preliminary report.* J Neuro Oncol, 1995. **24**(1).

104. Hicke B J, Marion C, Chang Y F, Gould T, et al., *Tenascin-C aptamers are generated using tumor cells and purified protein.* J Biol Chem, 2001. **276**(52): p. 48644-48654.

105. Hasegawa M, Nakoshi Y, Muraki M, Sudo A, et al., *Expression of large tenascin-C splice variants in synovial fluid of patients with rheumatoid arthritis.* J Orthop Res, 2007. **25**(5): p. 563-568.

106. Riedl S, Tandara A, Reinshagen M, Hinz U, et al., *Serum tenascin-C is an indicator of inflammatory bowel disease activity.* Int J Colorectal Dis, 2001. **16**(5): p. 285-291.

107. Tanaka H, El-Karef A, Kaito M, Kinoshita N, et al., *Circulating level of large splice variants of tenascin-C is a marker of piecemeal necrosis activity in patients with chronic hepatitis C.* Liver Int, 2006. **26**(3): p. 311-318.

108. Spinale F G, Coker M L, Bond B R and Zellner J L, *Myocardial matrix degradation and metalloproteinase activation in the failing heart: a potential therapeutic target.* Cardiovasc Res, 2000. **46**: p. 225-238.

109. Pfeffer M A, Pfeffer J M, Fishbein M C, Fletcher P J, et al., *Myocardial infarct size and ventricular function in rats.* Circ Res, 1979. **44**(4): p. 503-512.

110. Podesser B K, Schirnhofer J, Bernecker O Y, Kroner A, et al., *Optimizing ischemia/reperfusion in the failing rat heart--improved myocardial protection with acute ACE inhibition.* Circulation, 2002. **106**(12 Suppl 1): p. I277-I283.

111. Trescher K, Bernecker O, Fellner B, Gyongyosi M, et al., *Inflammation and postinfarct remodeling: overexpression of IkappaB prevents ventricular dilation via increasing TIMP levels.* Cardiovasc Res, 2006. **69**(3): p. 746-754.

112. Klocke R, Tian W, Kuhlmann M T and Nikol S, *Surgical animal models of heart failure related to coronary heart disease.* Cardiovasc Res, 2006. **74**(1): p. 29-38.

113. DATAPHARM Netsystems GMBH, *http://www.kardionet.de*.

114. Aukhil I, *Rattus norvegicus tenascin-C mRNA, partial cds, 1856 bp mRNA (U15550.1)* GenBank: U15550.1, 1994.

115. Thometich B, Schmidt W M, Bittner R E and Podesser B K, *Rattus norvegicus tenascin C (Tnc) mRNA, complete cds, 6155 bp mRNA.* GenBank: EU596506.1, 2008.

116. Nies D E, Hemesath T J, Kim J H, Gulcher J R, et al., *The Complete cDNA Sequence of Human Hexabrachion (Tenascin).* J Biol Chem, 1991. **266**(5): p. 2818-2823.

117. Weller A, Beck S and Ekblom P, *Amino acid sequence of mouse tenascin and differential expression of two tenascin isoforms during embryogenesis.* J Cell Biol, 1988. **107**: p. 2341-2349.

118. Matsumoto K, Hiraiwa N, Yoshiki A, Ohnishi M, et al., *Tenascin-C expression and splice variant in habu snake venom-induced glomerulonephritis.* Exp Mol Pathol, 2002. **72**(3): p. 186-195.

119. Adams M, Jones J L, Walker R A, Pringle J H, et al., *Changes in tenascin-C isoform expression in invasive and preinvasive breast disease.* Cancer Res, 2002. **62**(11): p. 3289-3297.

120. Chiquet-Ehrismann R, *What distinguishes tenascin from fibronectin?* FASEB J, 1990. **4**(9): p. 2598-2604.

121. Ljubimov A V, Saghizadeh M, Spirin K S, Khin H L, et al., *Expression of tenascin-C splice variants in normal and bullous keratopathy human corneas.* Invest Ophthalmol Vis Sci, 1998. **39**(7): p. 1135-1142.

122. Dang C, Gottschling M, Roewert J, Forschner T, et al., *Tenascin-C patterns and splice variants in actinic keratosis and cutaneous squamous cell carcinoma.* Br J Dermatol, 2006. **155**(4): p. 763-770.

123. Takeda A, Otani Y, Iseki H, Takeuchi H, et al., *Clinical significance of large tenascin-C spliced variant as a potential biomarker for colorectal cancer.* World J Surg, 2007. **31**(2): p. 388-394.

124. Frangogiannis N G, *The mechanistic basis of infarct healing.* Antioxid Redox Signal, 2006. **8**(11-12): p. 1907-1939.

125. Weisman H F, Bush D E, Mannisi J A, Weisfeldt M L, et al., *Cellular Mechanisms of Myocardial Infarct Expansion.* Circulation, 1988. **78**(1): p. 186-201.

126. Dobaczewski M, Gonzalez-Quesada C and Frangogiannis N G, *The extracellular matrix as a modulator of the inflammatory and reparative response following myocardial infarction.* J Mol Cell Cardiol, 2009.

127. Whittaker P, Boughner D R and Kloner R A, *Role of collagen in acute myocardial infarct expansion.* Circulation, 1991. **84**(5): p. 2123-2134.

128. El-Karef A, Kaito M, Tanaka H, Ikeda K, et al., *Expression of large tenascin-C splice variants by hepatic stellate cells/myofibroblasts in chronic hepatitis C.* J Hepatol, 2007. **46**(4): p. 664-673.

129. Zhao Y, Young S L and McIntosh J C, *Induction of tenascin in rat lungs undergoing bleomycin-induced pulmonary fibrosis.* Am J Physiol, 1998. **274**(6 Pt 1): p. 1049-1057.

130. Liakka K A and Autio-Harmainen H I, *Distribution of the extracellular matrix proteins tenascin, fibronectin, and vitronectin in fetal, infant, and adult human spleens.* J Histochem Cytochem, 1992. **40**(8): p. 1203-1210.

131. Aufderheide E, Chiquet-Ehrismann R and Ekblom P, *Epithelial-mesenchymal interactions in the developing kidney lead to expression of tenascin in the mesenchyme.* J Cell Biol, 1987. **105**(1): p. 599-608.

132. Weber P, Bartsch U, Rasband M N, Czaniera R, et al., *Mice deficient for tenascin-R display alterations of the extracellular matrix and decreased axonal conduction velocities in the CNS.* J Neurosci, 1999. **19**(11): p. 4245-4262.

133. Matsumoto K, Takayama N, Ohnishi J, Ohnishi E, et al., *Tumour invasion and metastasis are promoted in mice deficient in tenascin-X.* Genes Cells, 2001. **6**(12): p. 1101-1111.

134. Matsumoto K, Takahashi K, Yoshiki A, Kusakabe M, et al., *Invasion of melanoma in double knockout mice lacking tenascin-X and tenascin-C.* Jpn J Cancer Res, 2002. **93**(9): p. 968-975.

135. Guntinas-Lichius O, Angelov D N, Morellini F, Lenzen M, et al., *Opposite impacts of tenascin-C and tenascin-R deficiency in mice on the functional outcome of facial nerve repair.* J Neurosci, 2005. **22**: p. 2171-2179.

136. Mackie E J and Tucker R P, *The tenascin-C knockout revisited.* J Cell Sci, 1999. **112**(Pt 22): p. 3847-3853.

137. Fukamauchi F, Mataga N, Wang Y J, Sato S, et al., *Abnormal behavior and neurotransmissions of tenascin gene knockout mouse.* Biochem & Biophys Res Communications, 1996. **221**(1): p. 151-156.

138. Forsberg E, Hirsch E, Fröhlich L, Meyer M, et al., *Skin wounds and severed nerves heal normally in mice lacking tenascin-C.* Medical Sci, 1996. **93**(13): p. 6594-6599.

139. Trueblood N A, Xie Z, Communal C, Sam F, et al., *Exaggerated left ventricular dilation and reduced collagen deposition after myocardial infarction in mice lacking osteopontin.* Circ Res, 2001. **88**(10): p. 1080-1087.

140. Blankesteijn W M, Creemers E, Lutgens E, Cleutjens J P, et al., *Dynamics of cardiac wound healing following myocardial infarction: observations in genetically altered mice.* Acta Physiol Scand, 2001. **173**(1): p. 75-82.

141. Mao J R and Bristow J, *The Ehlers-Danlos syndrome: on beyond collagens.* J Clin Invest, 2001. **107**(9): p. 1063-1069.

142. Milting H, Ellinghaus P, Seewald M, Cakar H, et al., *Plasma biomarkers of myocardial fibrosis and remodeling in terminal heart failure patients supported by mechanical circulatory support devices.* J Heart Lung Transplant, 2008. **27**: p. 589-596.

143. Reardon D A, Zalutsky M R, Akabani G, Coleman R E, et al., *A pilot study: 131I-Antitenascin monoclonal antibody 81c6 to deliver a 44-Gy resection cavity boost.* Neuro Oncol, 2008. **10**(2): p. 182-189.

144. Zalutsky M R, Reardon D A, Akabani G, Coleman R E, et al., *Clinical experience with alpha-particle emitting 211At: treatment of recurrent brain tumor patients with 211At-labeled chimeric antitenascin monoclonal antibody 81C6.* J Nucl Med, 2008. **49**(1): p. 30-38.

7. ABBREVIATIONS

AD1+2: additional domain 1+2

AK: actinic keratosis

AMI: acute myocardial infarction

APS: Ammonium persulfate

ASMC: aortic smooth muscle cells

BCP: 1-bromo-3-chloro-propane

bFGF: basic fibroblast growth factor

BNP: brain natriuretic peptide

CHC: chronic hepatitis C

CK: creatin kinase

CNS: central nervous system

CRP: C-reactive protein

CTGF: connective tissue growth factor

CV: coefficient of variation

DAB: diaminobenzidine

DCIS: ductal carcinoma in situ

DCM: dilated cardiomyopathy

DMD/BMD: Duchenne/Becker muscular dystrophy

DMSO: dimethyl sulfoxide

dNTP: deoxyribonucleotide triphosphate

E: embryonic day

ECL: enhanced-chemiluminescence

ECM: extra cellular matrix

EDS: Ehler-Danlos Syndrome

EDTA: ethylene diamine tetraacetic acid

EF: ejection fraction

EGF: epidermal growth factor

EGF-L repeats: epidermal growth factor like repeats

EGTA: ethylene glycol tetra acetic acid

ELISA: enzyme-linked immunosorbent assays

EtOH: ethanol

FG: fibrinogen globe

FN: fibronectin

FN-III domains: fibronectin type III domains

For: forward

GAPDH: glyceraldehyde 3-phosphate dehydrogenase

GMEM: glial/mesenchymal extracellular matrix protein

H: hour

HCE: human corneal epithelial cells

HDL: high density lipoprotein

H&E staining: hematoxylin and eosin staining

HRP: horse radish peroxidase

HSCs: hepatic stellate cells

HSV: habu snake venom

IBD: inflammatory bowel disease

IDC: idiopathic dilated cardiomyopathy

IFN-γ: interferon γ

IHC staining: immunohistochemical staining

IL: interleukin

i.p.: intraperitoneal

i.m.: intramuscular

kDa: kilodalton

L: liter

LAD: left anterior descending coronary artery

LDH: lactate dehydrogenase

LDL: low density lipoprotein

LEF: lymphoid enhancer-binding factor

LV: left ventricle

MAb: monoclonal antibody

MACE: major adverse cardiac events

MAPK pathway: mitogen-activated protein kinase pathway

MHC: major histocompatibility complex

MI: myocardial infarction

Min: minutes

MMP: matrix metalloproteinases

NBT: nitro blue tetrazolium

NfκB: nuclear factor kappa-light-chain-enhancer of activated B cells

NT-proBNP: amino terminal fragment of proBNP

Ns: not significant

NYHA: New York Heart Association

OMI: old myocardial infarction

OPC: oligodendrocyte precursor cells

OPN: osteopontin

OSCC: oral squamous cell carcinoma

P6: postnatal day 6

PBS: phosphate buffered saline

PCR: polymerase chain reaction

PDGF: platelet-derived growth factor

PEO: pro-epicardial organ

PVDF: polyvinylidenfluorid

RAAS: renin-angiotensin-aldosterone system

Ras protein: rat sarcoma protein

Rev: reverse

RGD motive: contains amino acids: R = arginine, G = glycine and D = asparagine

RNA: Ribonucleic acid

ROS: reactive oxygen species

RT: room temperature

SCC: squamous cell carcinoma

SD: standard deviation

SDS: sodium dodecyl sulfate

SGOT: serum glutamate oxaloacetate transaminase

SMC: smooth muscle cells

SPARC: osteonectin (also known as BM-40)

SPX domain: serine-proline rich domain

TA domain: tenascin assembly domain

TBS: tris buffered saline

TBS-T: tris buffered saline with tween

TCF: T cell-specific transcription factor

TEMED: tetramethylethylenediamine

TGF-β: transforming growth factor β

TGF: transforming growth factor

TIMP: tissue inhibitors of matrix metalloproteinases

TN: tenascin

TN-C_L: large tenascin-C isoform

TN-C_S: small tenascin-C isoform

TNF-α: tumour necrosis factor α

TSP1: thrombospondin-1

TSP2: thrombospondin-2

8. APPENDIX

8.1. Rat TN-C: cDNA Sequence

Rattus norvegicus tenascin-C (TN-C) mRNA, complete cds (GenBank, EU596506)

```
   1 ccctacagat ctagagacac ctagccaatc caacctctac catgggggcc gtgrcctggc
  61 tattgccagg catcttccta gctttgtttg ccctcactcc tgaaggtggg gtcctcaaga
 121 aagtcatcag gcacaagcga gagagtgggc tgaacttgac cttgccagag gagaatcagc
 181 cagtggtgtt caaccatgtc tacaacatca agttgcccat gggttctcag tgctcagtgg
 241 atctagagtc aacgagtgga gagaaagacc tgagccccac accagagtcc agtggaagct
 301 tccaggagca tacagtggat ggggaaaatc agattgtgtt cacacaccgc atcaacatcc
 361 ctcgtcgggc ctgtggctgt gccgcagctc cagatgtgaa ggagctcctg agcagactgg
 421 aggaactgga gatgttggta tcttctctaa gggagcagtg caccatgggt acaggctgtt
 481 gcctccaacc tgcagaaggc cgtctggaca gcaggccctt ctgcagcggc aggggtaact
 541 tcagtgctga aggttgtggc tgtgtctgtg aaccaggctg gaaaggtccc aactgctctg
 601 agcctgaatg ccctggaaac tgtaatctca gaggccagtg ccttgatgga cagtgtatct
 661 gtgaccaggg tttcactggg gaagactgca gccagctagc ctgtcccaat gactgcaatg
 721 accagggcaa gtgtgtgaat ggggtctgtg tgtgcttcga aggctatgcc ggccttgact
 781 gtggcctgga agtctgccca gtgccgtgca gcgaggaaca cgggatgtgt gtggatggca
 841 ggtgtgtgtg caaagatggc tttgctggtg aagactgcaa tgagcccctt tgcttcaaca
 901 actgcaacaa ccgtgggcgg tgtgtggaga acgaatgcgt ctgtgatgag ggcttcacgg
 961 gcgaagactg cagcgagctc atttgcccca atgactgctt cgaccgaggt cgctgcatca
1021 acggcacctg ctactgtgaa gaaggtttca caggtgaaga ctgtggtgag ctcacctgcc
1081 ccaacaactg tcagggccat ggccagtgtg aagagggaca gtgtgtttgc aacgagggct
1141 ttgcaggggc agactgcagt gaaaagcggt gtcccgcaga ctgtcaccac catggccgct
1201 gtctcaacgg acagtgtgag tgtgacgatg ggttcacagg ggctgactgt ggggaactcc
1261 agtgccccaa tggctgcagt gggcatggcc gctgtgtcaa tgggcagtgt gtgtgtgacg
1321 agggctacac cggagaagac tgtagccaac ggcgatgccc caatgactgc cacaaccggg
1381 gtcactgtgt acagggcaaa tgcatatgtg agcaaggctt caaaggcttt gactgtagtg
1441 agatgagctg tcccaatgac tgccaccagc atggccgctg tgtgaatggc atgtgcatct
1501 gtgatgatga ctacactggg gaagactgca gagaccgccg ctgtccccgg gactgtagcc
1561 agcgggggcg ctgtgtggac ggacagtgca tttgtgagga tggtttcact ggttctgact
1621 gtgctgagct ctcctgccct ggtgactgcc acggccatgg ccgctgtgtg aatggccaat
1681 gcatctgcca cgagggcttc accggcraag actgcaaaga gcaaaggtgc cccagtgact
1741 gccatggcca aggccgctgt gaggacggcc aatgtatctg ccatgagggc ttcacaggcc
1801 tggactgtgg gcagcgctcc tgtcccaatg actgcagcaa ccagggacaa tgtgtggcag
1861 gccgctgcat ctgcaatgaa ggctacacag gggtagactg ctctgaggtg tcccctccca
1921 aagaccttat tgtgacagaa gtaacagagg agactgtara tctggcatgg gacaatgaga
```

1981 tgcgggtcac tgagtacctc attatgtaca cacccaccca tgctgatggc ctggagatgc
2041 agttccgtgt gcctggggac cagacatcta ccaccatccg ggagctggag ccaggagtgg
2101 agtacttcat tcgtgtgttc gccatcttgg agaacaagag gagcatccct gtcagtgcca
2161 gagttgccac ctacttgcct gcacctgaag gcctaaaatt caagtctatc aaggagacat
2221 ctgtggaagt agagtgggat cctctggaca tcgcttttga aacgtgggag atcattttca
2281 gaaatatgaa caaagaagat gagggagaga tcacaaaaag cttgaggagg ccagagacct
2341 cctaccgcca aactggcctg gctcctggcc aagaatatga aatatctctt cacattgtga
2401 aaaacaacac ccgaggccct ggcttgaaga aagtgaccac aactcgcctg gatgccccca
2461 gccaaattga ggtgagagac atcacagaca ctacagcact gatcacctgg tccaagccct
2521 tggctgaaat tgatagcatt gagctctcct atggcatcaa ggatgtgcct ggagaccgga
2581 ccaccatcga cctcacacat gaagacaacc agtactccat cgggaacctg aaacctgaca
2641 cggagtatga ggtgtccctc atctcccgca gagtggacat ggcaagcaac cctgccaagg
2701 agaccttcat cacaggcctg gatgctccca ggaatctccg tcgcgtctca cagacagaca
2761 acagcatcac cttggagtgg aggaatgtca aggcagacat tgatagttat agaattaagt
2821 atgcacctat ctctggaggt gaccatgctg agatagatgt tccaaagagc cagcaagcca
2881 caaccaaaac cacactcaca ggtctaaggc caggaactga atatggagtg ggcgtctctg
2941 ctgttaaggg agacaaggag ggcgatccag caaccatcaa tgcagccaca gaaattgatg
3001 cacccaggga cttacaggtg tctgagacca cacaagacag tctgacttta ttctggaaga
3061 cacctctggc caagtttgat cgttaccgcc tcaactacag cctccccaca ggccagtcaa
3121 tagagattca gctgccaaag gatgccacct cccatgtcct gacagacctg gagccagggc
3181 aagaatacac tgttctcctc accgctgaga agggcagaca taagagcaag cctgcgcgtg
3241 tgaaggcatc cacagaagaa gtaccttctc tggaaaatct caccgtgact gaggccggct
3301 gggatggcct cagactcaac tggactgcag atgacctggc ctatgagtac tttgttattc
3361 aggtacagga agccaacaag gtggagactg ctcacaactt cacagtactt ggtaacctcc
3421 ggactgcaga catcccgggc ctcaaggctg ccactcctta tagagtctcc atttatgggg
3481 tagctcgggg ctataaaaca cccgtgctct ctgctgagac cttcacaggg aaaactccca
3541 gtttgggaga ggtgactgtg gctgaggtgg gctgggatgc cctcaagctc aactggactg
3601 ctccagaagg agcctatacg aactttttca ttcaggtgct agaggctgac atgacccaga
3661 ctgtccagaa cctcacagtc ccagggggac tgaggtcagt ggacctacct gggctcaaag
3721 cagccacccg ctattacatc accgttcgag gggtcaccca ggacttcagc acagcccctc
3781 tctctgttga ggtcttgaca gaggagatcc ctcaactggg aggcttgtcc gtgactgagg
3841 tcagctggga cagccttaca ctcaactgga ccacagatga tctggcctat aagcacttta
3901 tcattcaggt gcaggaggcc aacaatgtag aggctgctca gaacctcaca gtatctggta
3961 gcctcagagt tgtggacatc ccaggcctca aggctgatac cccttataga gtctccatct
4021 atggggtgat ccagggctat agaacaccaa tgctctctgc tgatgtctcc acagccaaag
4081 aacctgaaat tggaaactta aatatttctg atgtaactcc tgagagcttc aatctctcct
4141 ggacagctac cgacgggatc ttcgacatgt ttactatcga aattattgat tctaataggt
4201 tgctgcagac agcagaacat aatatatctg gtgctgaacg aactgcccac atctcgggcc
4261 ttccacctag tactgatttc attgtctacc tctctggaat tgctcccagc atccgtacca
4321 aaaccatcag taccacagcc accacagaag ctgaaccgga agttgacaac cttctagttt
4381 cagatgctac tccagacggt ttctgtctgt cctggactgc tgatgaaggg atattcgaca
4441 gttttgttat caggatcaga gataccaaaa agcaatctga accacaagaa ataaccctcc
4501 cttcccccga ccgtaccagg gacataacag gtctcagaga ggccactgag tacgaaattg

4561 aactctatgg aataagccgt ggaaggcgat cccagccagt cagtgccata gcaacaacag
4621 ccatgggctc tccgaaggaa atcatgttct cagacatcac tgaaaatgca gccacagtca
4681 gctggagggc accgactgct caggtggaga gtttccggat tacttatgtg cctgtaacag
4741 gaggtccccc atccatggtg accgtggatg ggacggatac tgagacccga ctggtgaggc
4801 tcacccctgg agtggagtac cacgtcagtg tgattgccat gaagggattt gaagaaagtg
4861 atccggtctc ggggtctcta atcacagctc tcgatggtcc atctggcctt ctgacagcca
4921 acatcacaga ctcagaagcc ttggccatgt ggcagccggc cattgccact gtggacagtt
4981 atgtcatctc ctacacaggg gagagagtgc cagaaattac ccgcacagtg tctgggaata
5041 cagtggagtt tgaactacat gacctggagc ctgccacaga gtacacactg agtgtctttg
5101 cagagaaagg tcaccagaag agttctacca tcgctacgaa atttaccaca gacctggatt
5161 ccccaagaga attgactgct actgaggttc agtcagaaac tgccttcctc acctggagac
5221 ctccccgggc atcggtcact ggatacctcc tggtctatga gtctgtggat ggtacagtca
5281 aggaagtcat tgtggggcct gacaccacct cctacagcct ggcagacctg agcccatcca
5341 cccactacac agcaagaatc caggcattga gtgggtccct gaggagcaaa ctgatccaaa
5401 ccatcttcac cacaattgga ctcctatatc cattccctag ggattgctct caagcaatgt
5461 tgaatggcga caccacctct ggcctctata ccatctatat aaatggtgac aagactcaag
5521 cactggaagt ctactgtgat atgacctctg atggaggtgg atggatcgtt ttcctgagac
5581 gcaaaaatgg acgtgaggac ttctatcgaa actggaaggc ctatgccact gggtttggag
5641 accgcagaga agaattctgg cttggactgg ataacctgag caaaatcaca gcccaagggc
5701 aatatgagct ccgggtggac ctacaagacc atggggagtc agcctatgct gtgtatgaca
5761 ggttcagtgt tggagatgcc aagagtcgct acaagctgaa ggtagaagga tacagtggaa
5821 cggcaggtga ctccatgaac tatcacaatg gtagatcctt ctctacctat gacaaggaca
5881 cagactcagc catcaccaac tgtgccctgt cctacaaagg agctttctgg tataagaact
5941 gtcatcgtgt caacctgatg ggcagatatg gggacaataa tcacagtcag ggtgttaact
6001 ggttccactg gaagggccat gagtactcaa tccagtttgc ggagatgaaa ctaagaccca
6061 gcaacttccg aaatctggaa ggcaggcgta agcgggcata aatcccaggg acaatttggt
6121 gagagaggaa tggggcccag agaaaacagg atttt

8.2. Rat TN-C: Translation

MGAVXWLLPGIFLALFALTPEGGVLKKVIRHKRESGLNLTLPEE
NQPVVFNHVYNIKLPMGSQCSVDLESTSGEKDLSPTPESSGSFQEHTVDGENQIVFTH
RINIPRRACGCAAAPDVKELLSRLEELEMLVSSLREQCTMGTGCCLQPAEGRLDSRPF
CSGRGNFSAEGCGCVCEPGWKGPNCSEPECPGNCNLRGQCLDGQCICDQGFTGEDCSQ
LACPNDCNDQGKCVNGVCVCFEGYAGLDCGLEVCPVPCSEEHGMCVDGRCVCKDGFAG
EDCNEPLCFNNCNNRGRCVENECVCDEGFTGEDCSELICPNDCFDRGRCINGTCYCEE
GFTGEDCGELTCPNNCQGHGQCEEGQCVCNEGFAGADCSEKRCPADCHHHGRCLNGQC
ECDDGFTGADCGELQCPNGCSGHGRCVNGQCVCDEGYTGEDCSQRRCPNDCHNRGHCV

QGKCICEQGFKGFDCSEMSCPNDCHQHGRCVNGMCICDDDYTGEDCRDRRCPRDCSQR
GRCVDGQCICEDGFTGSDCAELSCPGDCHGHGRCVNGQCICHEGFTGXDCKEQRCPSD
CHGQGRCEDGQCICHEGFTGLDCGQRSCPNDCSNQGQCVAGRCICNEGYTGVDCSEVS
PPKDLIVTEVTEETVBLAWDNEMRVTEYLIMYTPTHADGLEMQFRVPGDQTSTTIREL
EPGVEYFIRVFAILENKRSIPVSARVATYLPAPEGLKFKSIKETSVEVEWDPLDIAFE
TWEIIFRNMNKEDEGEITKSLRRPETSYRQTGLAPGQEYEISLHIVKNNTRGPGLKKV
TTTRLDAPSQIEVRDITDTTALITWSKPLAEIDSIELSYGIKDVPGDRTTIDLTHEDN
QYSIGNLKPDTEYEVSLISRRVDMASNPAKETFITGLDAPRNLRRVSQTDNSITLEWR
NVKADIDSYRIKYAPISGGDHAEIDVPKSQQATTKTTLTGLRPGTEYGVGVSAVKGDK
EGDPATINAATEIDAPRDLQVSETTQDSLTLFWKTPLAKFDRYRLNYSLPTGQSIEIQ
LPKDATSHVLTDLEPGQEYTVLLTAEKGRHKSKPARVKASTEEVPSLENLTVTEAGWD
GLRLNWTADDLAYEYFVIQVQEANKVETAHNFTVLGNLRTADIPGLKAATPYRVSIYG
VARGYKTPVLSAETFTGKTPSLGEVTVAEVGWDALKLNWTAPEGAYTNFFIQVLEADM
TQTVQNLTVPGGLRSVDLPGLKAATRYYITVRGVTQDFSTAPLSVEVLTEEIPQLGGL
SVTEVSWDSLTLNWTTDDLAYKHFIIQVQEANNVEAAQNLTVSGSLRVVDIPGLKADT
PYRVSIYGVIQGYRTPMLSADVSTAKEPEIGNLNISDVTPESFNLSWTATDGIFDMFT
IEIIDSNRLLQTAEHNISGAERTAHISGLPPSTDFIVYLSGIAPSIRTKTISTTATTE
AEPEVDNLLVSDATPDGFCLSWTADEGIFDSFVIRIRDTKKQSEPQEITLPSPDRTRD
ITGLREATEYEIELYGISRGRRSQPVSAIATTAMGSPKEIMFSDITENAATVSWRAPT
AQVESFRITYVPVTGGPPSMVTVDGTDTETRLVRLTPGVEYHVSVIAMKGFEESDPVS
GSLITALDGPSGLLTANITDSEALAMWQPAIATVDSYVISYTGERVPEITRTVSGNTV
EFELHDLEPATEYTLSVFAEKGHQKSSTIATKFTTDLDSPRELTATEVQSETAFLTWR
PPRASVTGYLLVYESVDGTVKEVIVGPDTTSYSLADLSPSTHYTARIQALSGSLRSKL
IQTIFTTIGLLYPFPRDCSQAMLNGDTTSGLYTIYINGDKTQALEVYCDMTSDGGGWI
VFLRRKNGREDFYRNWKAYATGFGDRREEFWLGLDNLSKITAQGQYELRVDLQDHGES
AYAVYDRFSVGDAKSRYKLKVEGYSGTAGDSMNYHNGRSFSTYDKDTDSAITNCALSY
KGAFWYKNCHRVNLMGRYGDNNHSQGVNWFHWKGHEYSIQFAEMKLRPSNFRNLEGRR
KRA

9. CURRICULUM VITAE

PERSONAL INFORMATION

Name:	**Mag. Barbara Thometich**
Nationality:	Austria
Date of birth:	2.4.1980
Email:	barbara.thometich@meduniwien.ac.at, barbara.thometich@gmx.net

EDUCATION

04/2006:	Doctoral thesis, Core Unit of Biomedical Research (Medical University of Vienna) and Ludwig Boltzmann Cluster for Cardiovascular Research, Vienna, Austria
02/2004:	Diploma thesis, Institute of Molecular Pathology (IMP), Vienna, Austria
10/1999:	Undergraduate studies in microbiology, University of Vienna, Austria
1990-1999:	High school, BG/BRG Bernoullistraße XXII
1986-1990:	Primary school

PRACTICAL EXPERIENCE

07/2001:	Baxter AG, Molecular pathology
07/2002:	Baxter AG, Molecular pathology

CONGRESSES

06/2008:	3rd Summer Conference of the Center of Anatomy & Cell Biology 2008
01/2008:	Kardiovaskuläre Forschungstage 2008
06/2007:	48. Österreichischer Chirurgenkongress
01/2007:	Kardiovaskuläre Forschungstage 2007
11/2006:	30. Seminar der österreichischen Gesellschaft für chirurgische Forschung

10. PUBLICATIONS

GenBank

Rattus norvegicus Tenascin C (Tnc) mRNA, complete cds. (bankit1077407, EU596506), **Thometich, B**., Schmidt, W. M., Bittner, R. E. and Podesser, B. K.

Oral Presentation

Expression of different tenascin-C isoforms in post myocardial infarction remodelling, **Thometich, B.,** Schmidt, W. M., Podesser, B. K., 3rd Summer Conference of the Center of Anatomy & Cell Biology 2008

Remodeling of the ascending aortic wall: is tenascin-C the key? Trescher, K., **Thometich, B.,** Holzinger, C., Vodrazka, M., Schor, I., Binder, K., Bergmann, P., Bernecker, O., Kassal, H., Paulitschke, V., Bankl, H. C., Sedivy, R., Bittner, R. E., Podesser, B. K., Kardiovaskuläre Forschungstage 2008, **Eur. Surg**., Vol. 40 Supplement Nr. 220

Reduced Tenascin-C Expression under Endothelin A-Receptor Blockade is crucial for the Development of Heart Failure post Myocardial Infarction, **Thometich, B.,** Dietl, W., Mitterer, G., Bauer, M., Trescher, K., Hasun, M., Baumgartner, A., Schmidt, W. M., Bittner, R. E., Podesser B. K., 48. Österreichischer Chirurgenkongress 2007, **Eur. Surg**., Vol. 39 Supplement Nr. 215/050

Tenascin-C as a key factor in the remodeling of the ascending aorta leading to chronic dilatation and acute Type A dissection, Trescher, K. M., **Thometich, B**., Holzinger, C., Vodrazka, M., Schor, I., Binder, K., Bergmann, P., Bernecker, O., Kassal, H., Bankl, H., Bittner, R. E., Podesser, B. K., 48. Österreichischer Chirurgenkongress 2007, **Eur. Surg**., Vol. 39 Supplement Nr. 215/050

Tenascin-C: A possible marker for LV remodeling after myocardial infarction in endothelin therapy, **Thometich, B**., Dietl, W., Mitterer, G., Bauer, M., Trescher, K., Hasun, M., Baumgartner, A., Schmidt, W. M., Bittner, R. E., Podesser, B. K., Kardiovaskuläre Forschungstage 2007, **Eur. Surg**., Vol. 39 Supplement Nr. 213/21

Poster Presentation

Tenascin-C expression pattern in post myocardial infarction remodelling, **Thometich B**., Kapeller B., Macfelda K., vfwf-Universitätsvorlesung 2009