



universität  
wien

# MASTERARBEIT

Titel der Masterarbeit

„On the Cranial Anatomy of the Porbeagle Shark,  
*Lamna nasus*: Investigations on Skeletal Labyrinth  
Morphology and Tooth Development and  
Structure“

verfasst von

Lisa Schnetz, BSc

angestrebter akademischer Grad

Master of Science (MSc)

Wien, 2015

Studienkennzahl lt.  
Studienblatt:

A 066 833

Studienrichtung lt.  
Studienblatt:

Masterstudium Ökologie

Betreut von:

Univ.-Prof. Dr. Jürgen Kriwet, Dipl.-Geol.



# TABLE OF CONTENTS

<b>1. Abstract.....</b>	<b>5</b>
<b>2. Zusammenfassung.....</b>	<b>7</b>
<b>3. Introduction .....</b>	<b>9</b>
3.1. Phylogenetic relationships of extant elasmobranchs .....	9
3.2. The Order Lamniformes .....	10
3.3. The Lamnidae .....	11
3.4. The porbeagle shark <i>Lamna nasus</i> Bonaterre 1788.....	12
3.5. <i>Lamna nasus</i> populations in the North Atlantic and Mediterranean Sea .....	14
3.6. Goals.....	15
<b>4. PART A: INNER EAR .....</b>	<b>16</b>
4.1. Materials and Methods.....	18
4.2. Results.....	20
4.3. Discussion .....	23
<b>5. PART B: TOOTH DEVELOPMENT AND STRUCTURE .....</b>	<b>28</b>
5.1. Materials and Methods.....	30
5.2. Results.....	32
5.3. Discussion .....	35
<b>6. Conclusion.....</b>	<b>37</b>
<b>7. Acknowledgments.....</b>	<b>39</b>
<b>8. Literature cited .....</b>	<b>41</b>
<b>Curriculum Vitae.....</b>	<b>49</b>



## 1. ABSTRACT

The porbeagle shark, *Lamna nasus*, belongs to the order Lamniformes, a group consisting of highly specialised sharks inhabiting all major ocean basins. It is a pelagic predator, displaying fast swimming behaviour and endothermy. Porbeagle populations have declined severely in the North Atlantic and Mediterranean Ocean due to overexploitation and there are no signs of recovery to date. Still, little is known about their biology and anatomy, and pressure is rising as species numbers fall. Here, high-resolution micro-computed tomography scanning and three-dimensional reconstruction was used to reveal the inner ear morphology and shape as well as tooth structure and development in the porbeagle cranium to contribute to the morphological anatomy of this highly peculiar shark. These results constitute the first reconstruction of the skeletal labyrinth within the lamnid family and the first application of CT scanning to study tooth development in *Lamna nasus*. The skeletal labyrinth of the porbeagle is of compact, massive shape with almost circular, thick semicircular canals. The teeth files contain eight teeth, of which two are functional, and the development of the osteodont histotype can be clearly resolved. Implications between tooth structure and food source can be drawn and members of the lamnids seem to display the osteodont type. Correlations of the inner ear morphology and shape with the locomotion behaviour in *Lamna nasus* are difficult to make as information on such correlations are still unavailable for most elasmobranchs. Fast swimming fish are expected to possess narrow canals with a small internal radius, indicating high manoeuvrability. The porbeagle does not appear to show these features. Even though the data described here provides a first insight into lamnid inner ear and teeth features by using micro-CT scanning, comparative data on these cranial features is still lacking to a high degree in both extinct and extant elasmobranchs.



## 2. ZUSAMMENFASSUNG

Der Heringshai, *Lamna nasus*, gehört zur Ordnung der Lamniformes, einer Gruppe von hochspezialisierten Haien, die alle größeren Ozeanbecken bewohnen. Er ist ein pelagischer Räuber, der ein schnell schwimmendes Verhalten und Endothermie aufweist. Die Heringshai-Populationen sind im Nordatlantik und Mittelmeer gravierend zurückgegangen, als Resultat von Überfischung, und bis jetzt gibt es keine Zeichen einer Erholung dieser Reduktion. Sehr wenig ist über ihre Biologie und Schädelanatomie bekannt und der Druck erhöht sich, je mehr die Artenzahlen zurückgehen. Wir verwenden hochauflösende Computertomographie und dreidimensionale Rekonstruktion, um die Innenohrmorphologie und –form sowie die Zahnstruktur und die Zahnentwicklung im Heringshaischädel aufzuzeigen und um zu der morphologischen Anatomie dieses hochspezialisierten Hais beizutragen. Erstmals können wir somit mittels Computertomographie eine Rekonstruktion des Skelettlabyrinthes sowie eine erste Studie zur Zahnentwicklung von *Lamna nasus* und innerhalb der Familie der Lamnidae präsentieren. Das Skelettlabyrinth des Heringshais ist kompakt und massiv gebaut und weist fast kreisförmige, dicke Bogengänge auf. Die Zahnreihe besteht aus acht Zähnen, von denen zwei funktionell sind, und auch die Entwicklung eines osteodonten Zahntyps kann genau belegt werden. Verbindungen zwischen Zahnstruktur und Nahrungsquelle können hergestellt werden und Mitglieder der Lamnidae scheinen den osteodonten Zahntyp zu besitzen. Korrelationen zwischen der Innenohrmorphologie sowie –Form und des Fortbewegungsverhaltens sind für *Lamna nasus* schwierig abzuleiten, da es generelle Informationen zu solchen Korrelationen für Elasmobranchii kaum gibt. Es wird vermutet, dass schnell schwimmende Fische schmale Bogengänge mit einem kleinen internen Radius besitzen, was auf hohe Manövrierbarkeit weist. Der Heringshai weist diese Eigenschaften jedoch nicht auf. Obwohl die Daten, die hier beschrieben wurden, mittels Computertomographie einen ersten Einblick in die Innenohr- und Zahnmerkmale von Lamnidae geben, fehlen vergleichbare Informationen dieser Schädelmerkmale von sowohl ausgestorbenen als auch rezenten Elasmobranchii.



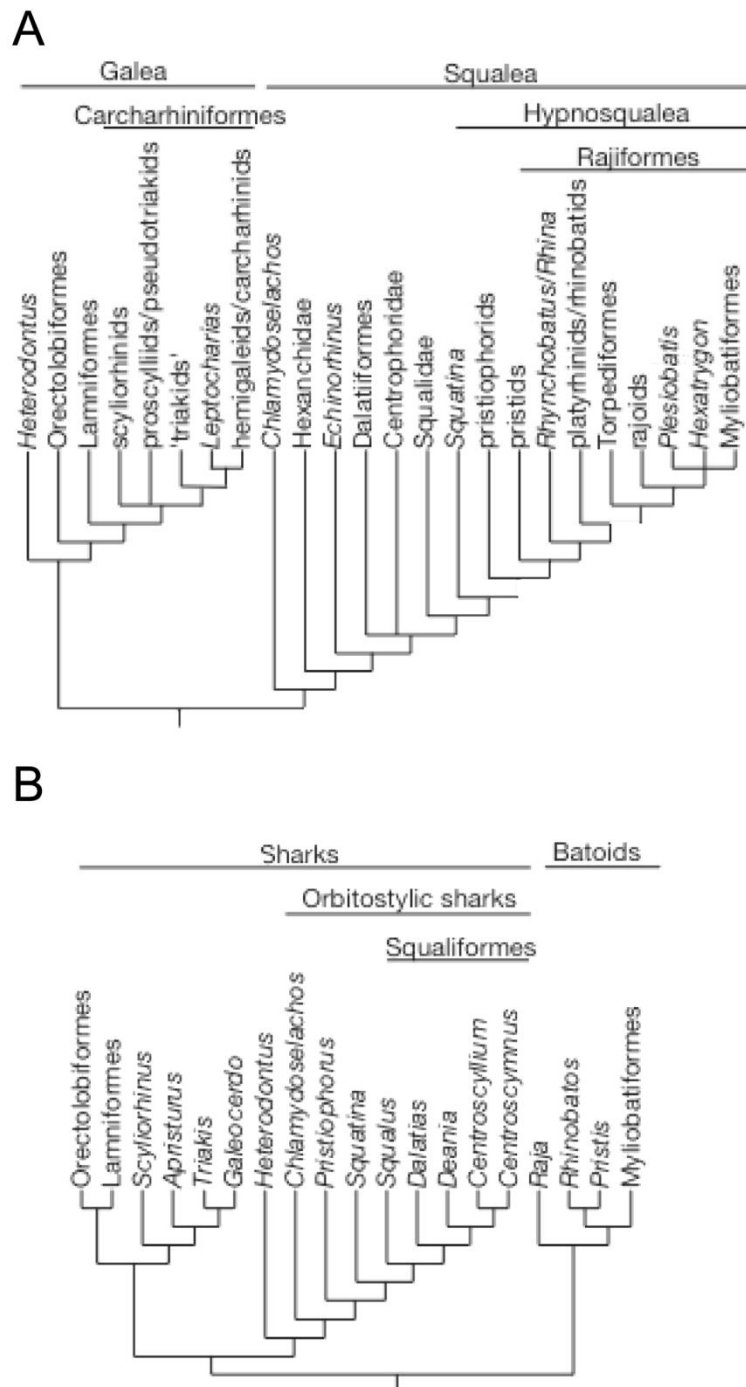


### 3. INTRODUCTION

#### ***3.1. Phylogenetic relationships of extant elasmobranchs.***

The systematics and evolution of living elasmobranchs are a controversial subject, both due to incomplete research and large gaps in the fossil record of extinct and living groups. The Elasmobranchii include all recent sharks and rays and form a monophyletic group within the Chondrichthyes, opposite to the sister taxon Holocephali (Compagno et al., 2005). Elasmobranch fossils are largely limited to isolated teeth only. Skeletal remains other than teeth are scarce and known from just a limited number of sites (Underwood, 2006).

Modern elasmobranchs are thought to have emerged and diversified intensely between the Late Jurassic and Early Cretaceous (Kriwet and Klug, 2008; Heinicke et al., 2009). Radiation then led to an increasing diversity of most extant clades between the Early and Late Cretaceous (Underwood, 2006). Phylogenetic relationships within both recent and extinct Elasmobranchii have been debated intensely for decades. Especially the question whether sharks and rays, batoids, form two independent monophyletic groups or need to be grouped together is of particular concern. From morphological data, several authors proposed a close relationship between batoids and both Pristiophoriformes, sawsharks, and Squatiniformes, angel sharks (Shirai, 1992; Shirai, 1996; de Carvalho, 1996). These together with the orders Squaliformes, Hexanchiformes, and Echinorhiniformes form the Hypnosqualean clade or later termed Squalea (Fig. 1). This so-called 'Hypnosqualean hypothesis' grouped all other shark orders together as Galea. Thus, living elasmobranchs can be divided into two groups, the Squalea and the Galea. However, data from both nuclear and mitochondrial sources neglect this hypothesis, suggesting a basal divergence of sharks and rays, Batoidea (e.g. Douady et al., 2003; Winchell et al., 2004; Heinicke et al., 2009). This is also congruent with fossil records of the first batoid appearance in the latest Triassic or basal Jurassic (Underwood, 2006), indicating a rather old divergence between sharks and batoids (Heinicke et al., 2009).



**Fig. 1.** The two main elasmobranch phylogenies discussed here from (A) morphological and (B) molecular characters (taken from Underwood, 2006).

### 3.2. The Order Lamniformes.

Within the sharks, there are the two major divisions, galeomorphs and squalimorphs (Compagno, 1973; Compagno, 1977; Heinicke et al., 2009). In the galeomorphs, the mackerel sharks of the order Lamniformes include some of the largest and most

specialised species inhabiting all major oceans from high to low latitudes worldwide (Compagno, 2001). The lamniform sharks form a well-defined monophyletic group and most phylogenetic relationships within the order are resolved (Compagno, 1977; Naylor et al., 1996; Heinicke et al., 2009). First fossil records of lamniform sharks date back to the lower Cretaceous (Cappetta, 2012) and the divergence of Lamniformes with the sister order Carcharhiniformes is thought to have occurred at around 185 Ma (Heinicke et al., 2009). Most lamniform sharks are pelagic predators but some also frequent shallow coastal waters and coral reefs (Compagno, 2001; Cappetta, 2012). The mackerel sharks consist of seven families, 10 genera and 15 species, including two of the three known planktivorous sharks to date (Compagno, 2001). Lamniform sharks are characterised by features such as two dorsal fins, a single anal fin, five broad gill slits, a well developed and tripodal rostrum, eyes positioned lateral to dorsolateral and without a nictitating membrane and a wide, large mouth extending behind the eyes (Nelson, 2006; Cappetta, 2012).

### **3.3. The Lamnidae.**

Within the order Lamniformes, the family Lamnidae is probably the most prominent one, with some of the largest active predatory sharks, in three recent genera: *Carcharodon*, *Isurus* and *Lamna*. Five species exist to date, including the great white shark, *Carcharodon carcharias*, the longfin and shortfin makos, *Isurus paucus* and *Isurus oxyrinchus*, and the porbeagle, *Lamna nasus*, and the salmon shark, *Lamna ditropis* (Compagno, 2001). The first appearance of this family is dated back to the lower Paleocene, from the Danian age on (Cappetta, 2012). During this time, trans-equatorial warm surface water started to dominate the ocean's circulation pattern (Bernal et al., 2001) which may have provided optimal conditions for lamnid ancestors to evolve and diversify.

Lamnidae possess a set of unique traits such as rather small second dorsal and anal fins, large teeth of tearing or cutting type with few files, pointed snouts with weakly protrusible jaws, a distinctively lunate caudal fin, upper and lower lip-grooves and a fifth gill slit which extends below and in front of the pectoral origin (Nelson, 2006; Cappetta, 2012). Lamnid sharks are easily recognizable as they are heavily built sharks, with a highly specialised spindle shaped body and large dark eyes

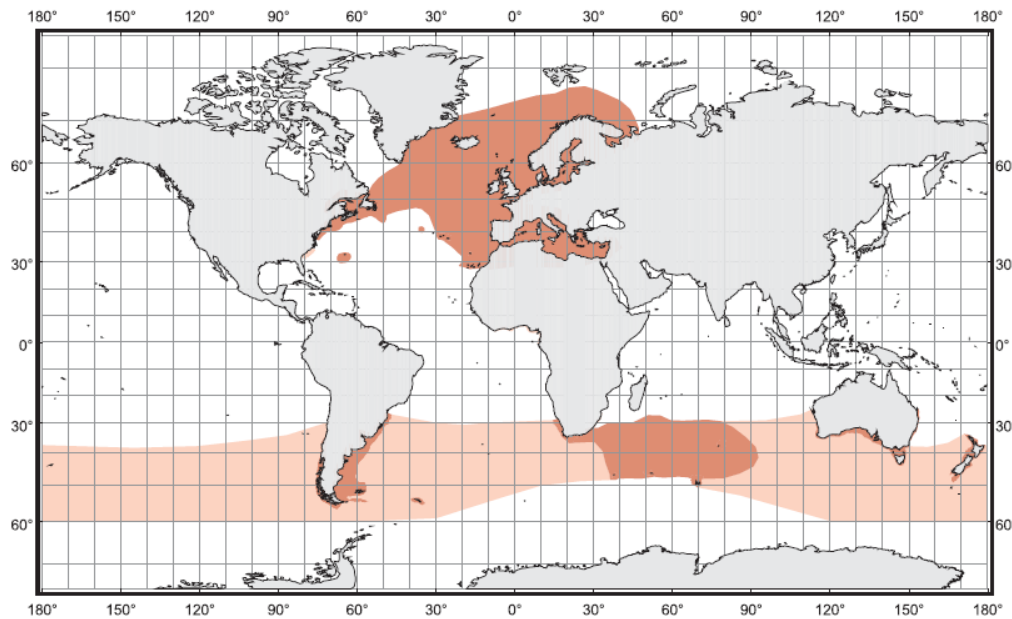
(Compagno, 2001). Maximum length is estimated to reach up to 6.4 m in the great white Shark (Compagno, 2001). The sharks within this family are counted to the fast swimming fish, with *Isurus oxyrinchus* thought of as the fastest swimming shark and one of the most active swimmers (Compagno, 2001).

They inhabit tropical to cool temperate marine waters all around the world, both continental and oceanic, though they are more counted to the pelagic species (Compagno, 2001; Nelson, 2006). Lamnidae are ovoviviparous and females nurture their young through oophagy: After first absorbing the external yolk sac, the embryos start actively feeding on the yolk-filled nutrient rich ova capsules (Jensen et al., 2002).

Lamnids sharks can be distinguished from all other Chondrichthyans and lamniform families by the possession of a unique morphological trait, the *retia mirabilia* (Fudge and Stevens, 1996). These vascular counter current heat exchangers located in various body tissues allow lamnids to preserve metabolically produced heat to keep their body temperature significantly higher than that of the surrounding water, thus making them endothermic. (Carey et al., 1981; Carey et al., 1982; Anderson and Goldman, 2001; Goldman et al., 2004). Lamnidae keep their body temperatures up to 15.6°C above sea surface temperatures (Anderson and Goldman, 2001), with a maximum temperature elevation of 21.2°C reported within the stomach of *Lamna ditropis* (Goldman et al., 2004). The ability to retain metabolic heat also allows lamnids to sustain their activity in colder waters, unlike other sharks (Bernal et al., 2001; Goldman et al., 2004; Pade et al., 2009).

### **3.4. The porbeagle shark *Lamna nasus* Bonaterre 1788.**

*Lamna nasus*, or porbeagle shark, is a large cold temperate pelagic shark of the family Lamnidae, distributed in the North Atlantic (including the Mediterranean Sea) and circumglobally in temperate waters of the South Atlantic, southern Indian, Pacific and Antarctic Ocean (Fig. 2) (Compagno, 2001). Fossil records of *Lamna nasus* date back to the lower Pliocene, from the Zanclean to recent time (Cappetta, 2012) and possibly even further back with the evidence of a fossil rostrum from the upper Miocene (Mollen, 2010).



**Fig. 2.** Distribution map of *Lamna nasus*. Distribution ranges from major parts of the North Atlantic to the South Atlantic, southern Indian and Pacific Ocean and further to the Antarctic Ocean (taken from Compagno, 2001). Centres of distribution are marked in darker colour.

*Lamna nasus* is a long living species (Campana et al., 2002), with longevity estimates of more than 40 years (Natanson et al., 2002). Maturity is reached at different age stages depending on the population, with eight years for males and 13 years for females in the North Atlantic (Jensen et al., 2002) and 8-11 years and 15-18 years around New Zealand (Francis et al., 2007). *Lamna nasus* is ovoviviparous and, as with all other large sharks, shows low fecundity (Francis and Stevens, 2000; Jensen et al., 2002). Litter sizes range from three to six, with an average of four, on an annual basis (Jensen et al., 2002). The diet of the porbeagle primarily consists of pelagic teleosts, including herring, mackerel and lancetfish, as well as groundfish and cephalopods in minor quantities (Joyce et al., 2002). Feeding behaviour has been found to change with geographic area and season in the porbeagle, shifting to the available prey spectrum on site (Joyce et al., 2002).

Satellite-linked tagging in the eastern Atlantic showed that porbeagle sharks move short to moderate distances, through most of the water column on a regular basis but also spend long periods of time near the surface (Pade et al., 2009; Saunders et al., 2011). They inhabit shallower depths during spring and summer with an area fidelity

to coastal and shelf habitats and particular areas as well as deeper waters during the winter season (Pade et al., 2009). Vertical distribution of porbeagles is rather broad, with measurements from 0 to 700 m depths via tagging (Saunders et al., 2011). Pade and colleagues (2009) also proposed that the physiological endothermy *Lamna nasus* displays could be advantageous at higher latitudes for exploitation of prey resources that become unavailable to competing predators such as ectothermic sharks. Porbeagles are active in a broad temperature spectrum from around 2°C minimum to 23°C maximum respectively (Francis and Stevens, 2000; Campana and Joyce, 2004). In the northwest Atlantic, most sharks were caught in temperatures around 5 to 10 °C (Campana and Joyce, 2004).

### **3.5. *Lamna nasus* populations in the North Atlantic and Mediterranean Sea.**

*Lamna nasus* belongs to the large predatory shark species that are declining rapidly all around the world. Porbeagle populations have been decreasing in both the western and eastern North Atlantic and the Mediterranean Sea (Stevens et al., 2006). The porbeagle shark is especially vulnerable to overexploitation and by-catch due to its slow growth rate, low fecundity and late sexual maturity (Natanson et al., 2002; Jensen et al., 2002). *Lamna nasus* has been excessively fished and utilized for human consumption since the early 20<sup>th</sup> century, with first the eastern and subsequently the western North Atlantic fisheries collapsing after heavily overexploiting the fish stocks (Compagno, 2001; Campana et al., 2008; Campana et al., 2013). Mainly Denmark and Norway started fishing for porbeagles in the North-East Atlantic in the 1930s and moved to fishing grounds in the North-West Atlantic when the stocks were almost depleted by the 1960s, later followed by the Canadian fishery (Campana et al., 2008). Consequently, stocks became uneconomical and overfished in the western North Atlantic by 1989 (Campana et al., 2008).

Porbeagle populations in the Southern Ocean are not a target of commercial fishery directly to date. Data on population dynamics is inferred mostly from by-catch in tuna longline and midwater trawl fisheries. There is little information on the status of the porbeagle in the Southern Ocean and there are no reports investigating whether there is a decline of this species compared to the North Atlantic (e.g. Francis et al., 2007).

The Mediterranean Sea has seen the highest loss of predatory sharks in recent years, and *Lamna nasus* specimens have almost disappeared from any records (Ferretti et al., 2008; Scacco et al., 2012). Declines in both abundances and biomass of 99.99% over a span of 56 years were calculated from both sightings and catches (Ferretti et al., 2008). Sightings of *Lamna nasus* have been scarce in general, with only few recordings over decades: Sperone and colleagues (2012) reported only two sightings of porbeagles from extensive surveys between the years 2000 to 2009 and only on the Tyrrhenian side of southern Italy. In 2010 and 2011, two specimens, one subadult and one adult, were caught in the central Adriatic Sea as by-catch by artisanal fishery (Scacco et al., 2012).

Even though *Lamna nasus* populations have been decreasing dramatically over the past century, management plans are rather scarce and unregulated, with different quota and TACs given by the EU and Canada (Stevens et al., 2006). Very little is known about the biology of porbeagles, making it more difficult to regulate and define management plans for this species (Compagno, 2001; Pade et al., 2009).

### **3.6. Goals.**

Empirical data on skeletal morphology of early shark-like fish is scarce and descriptions of cranial features of both extinct and modern elasmobranchs are even rarer (Maisey, 2004a). Craniate endocranial morphology has considerable potential for both phylogenetic and behavioural purposes, especially when fossils only contain the cranium or teeth. With non invasive CT scanning, internal features can now be examined and illustrated rather easily. The following investigations aim at describing the skeletal labyrinth morphology and tooth development and stages in *Lamna nasus* using high-resolution computed tomography. Correlations will be drawn between morphologies and behavioural responses regarding both the inner ear and teeth to gain further insight in the biology of the porbeagle shark.

## **4. PART A – INNER EAR MORPHOLOGY**

Mechanoreception in fish involves the detection of water movements using two major systems: the lateral line and the inner ear (Helfman et al., 2009). While the lateral line system detects disturbances in the water, the inner ear accounts for fish equilibrium, balance and hearing (Bone and Moore, 2008; Helfman et al., 2009). Unlike tetrapods, whose ear system is formed of up to three different regions (outer, middle and inner ear), fish only possess the inner part which contains the sensory receptors responsible for hearing (Maisey, 2001).

The gnathostome inner ear is composed of the membranous labyrinth forming a closed system with its three semicircular canals (anterior, posterior and lateral) and the utricle, saccule and lagena chambers and enclosed by the skeletal labyrinth consisting of cartilaginous or bony structures (Platt and Popper, 1981; Maisey, 2001; David et al., 2010). However, morphology of the inner ear differs considerably between vertebrate taxa and comparisons between different groups for phylogenetic purposes are common (Maisey, 2001). For equilibrium and balance in gnathostomes, utricle and saccule both account for the detection of linear velocity, while the semicircular canals process angular acceleration of the head (Jeffrey and Cox, 2010; David et al., 2010; Pfaff et al., 2015). The shape of the inner ear, especially concerning the semicircular canals, has been correlated to the mode of locomotion and agility in mammals mainly, focussing on extant and extinct primates, cetaceans and rodents (Spoor et al., 2002; Spoor et al., 2007; Pfaff et al., 2015).

Elasmobranchs display several morphological characteristics of the inner ear that distinguish them from modern holocephalans and teleosts (mainly from Maisey, 2001). The posterior semicircular canal is separated from the anterior and lateral ones and is connected only via a short duct with the vestibular region and the base of the endolymphatic duct. Additionally, the posterior semicircular canal describes, contrary to its name, an almost complete circle. A connection from a depression in the back of the skull to the endolymphatic ducts in the semicircular canals, the fenestra ovalis or perilymphatic fenestra, is presumed to enhance hearing by directing sound to the sensory area of the inner ear (Hueter et al., 2004). The semidirectional phonoreception in elasmobranchs involves primarily the posterior semicircular canal, the crista neglecta and the perilymphatic fenestra. Elasmobranchs



also have an endolymphatic duct that connects the sacculus with an opening on the dorsal side of the brain (Hueter et al., 2004). Via this duct, exogenous matter such as sand grains regularly enters the inner ear and sacculus of elasmobranchs. Endolymphatic ducts are closed in teleosts, hence these grains can only be found in elasmobranchs (Maisey, 2001).

Here, we describe for the first time to our knowledge the inner ear morphology of a fast swimming lamnid shark, *Lamna nasus* Bonaterre 1788, using high-resolution computed tomography ( $\mu$ CT). In order to construct a correct model of the inner ear anatomy in fast swimming lamnids, we also included an inner ear scan of *Isurus sp.*, a mako shark and presumably the fastest swimming shark to date. We additionally draw conclusions on the semicircular canal shape of elasmobranchs and the type of locomotion based on previous assumptions in the literature.

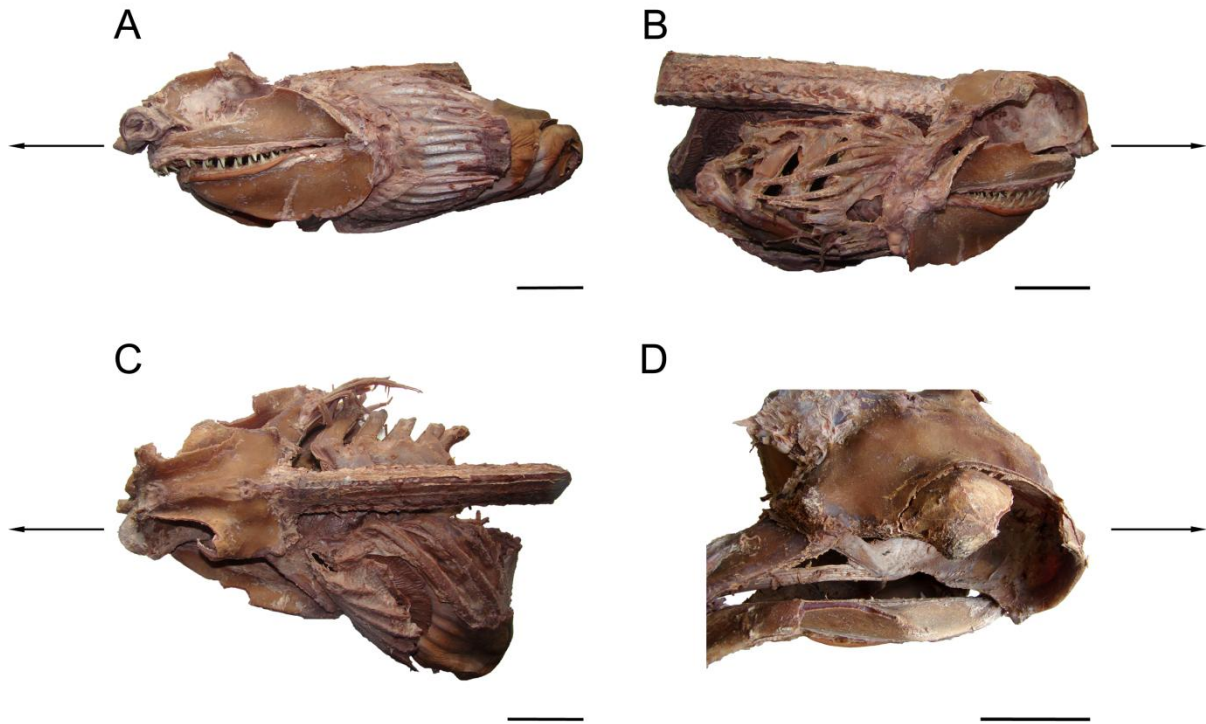
#### 4.1. MATERIALS AND METHODS

An adult *Lamna nasus* braincase, including both Chondrocranium and Splanchiocranium, preserved in a formaldehyde-alcohol mixture of unknown concentration was used for the following investigations. The cranium was mostly intact, although the rostrum had been sawed off for unknown reason. Muscle and dermal tissue were still present to some extent, as well as the visceral arches including the gills and some of the vertebrae (Fig. 3). The braincase was obtained from the Wet Department of the Biology Department at the University of Vienna. Origin is the Mediterranean Sea, the exact region of capture is unknown. For comparison of the inner ear within the Lamnidae, an additional scan with a dried juvenile *Isurus sp.* cranium was made. The *Isurus sp.* cranium was obtained from the Department of Paleontology at the University of Vienna. The porbeagle specimen was first deposited in an ascending alcohol series for one month to wash out the formaldehyde and prepare the tissue for further handling. Next, parts were transferred into 96% ethanol for storage.

First, both the visceral arches and the jaws were separated from the neurocranium. The preparation of the jaws to investigate tooth development and structures will be further described in Part B of the study. The neurocranium was manually dissected using scalpels, tweezers, scissors and brushes to remove as much soft tissue as possible. A SkyScan1173 microCT scanner (Bulker microCT, Belgium) from the Department of Paleontology at the University of Vienna was used to gain insights into the inner ear of the *Lamna nasus* as well as the juvenile *Isurus sp.* specimen. High-resolution computed tomography, or CT scanning, projects sequential radiographic images from a range of angular positions around an object to produce a cross-sectional view of specific areas of this object (Burghardt et al., 2011). With  $\mu$ CT technique, three-dimensional images with a spatial resolution between 1 and 100  $\mu$ m of an object can be obtained in a rapid, non-destructive way (Burghardt et al., 2011).

Settings used for scanning the inner ear were as following: 130kV source voltage, 61  $\mu$ A source current, 28.5  $\mu$ m voxel size (equivalent to the resolution used), brass 0.25mm filter, 2000ms exposure time, 0.200 deg. rotation step, frame averaging 3 and random movement 20. The CT data set was then further processed to create a 3D reconstruction of the inner ear using Amira (version 5.4.1, FEI Visualization Sciences Group, Oregon, United States). For comparison with the *Isurus sp.*

cranium, 2D models from the CT scans were used. A position within the horizontal plane was chosen for both specimens to compare the inner ear dimensions and shape.

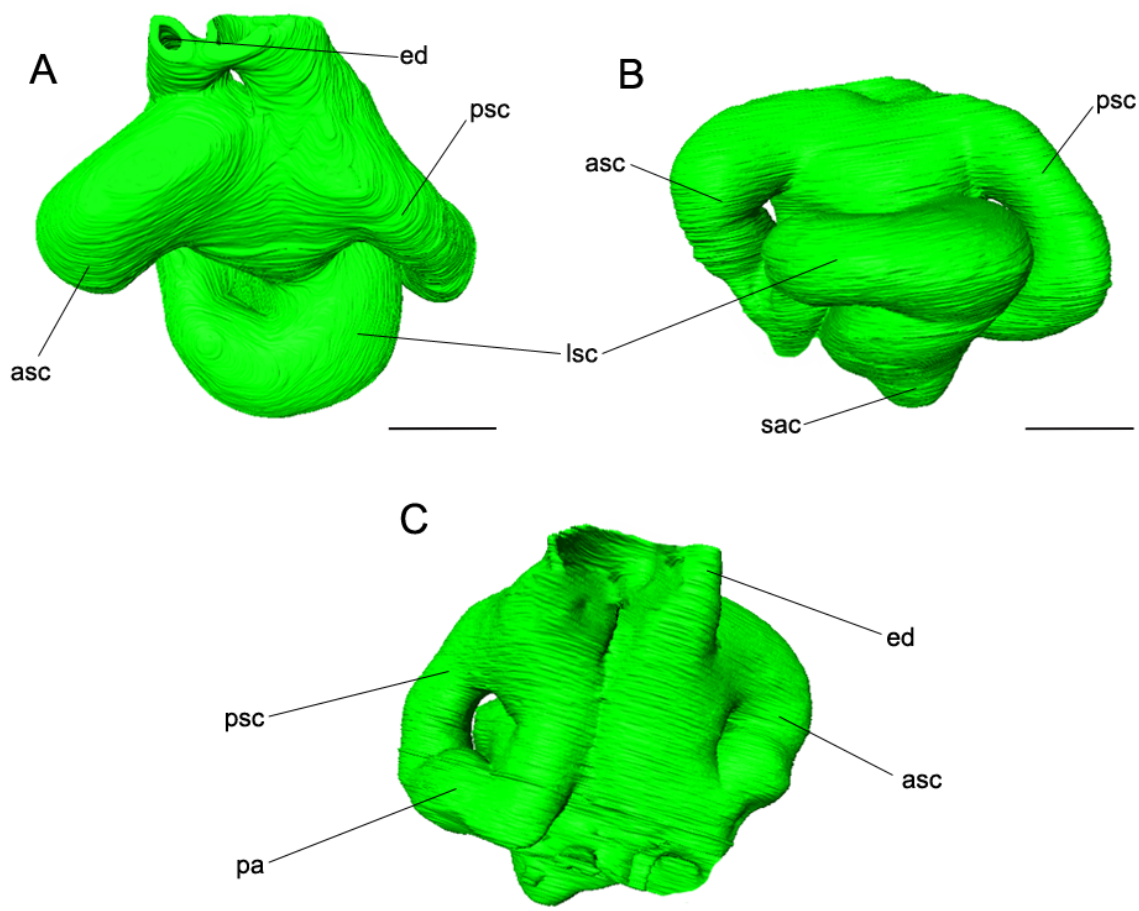


**Fig. 3.** Lateral view of the *Lamna nasus* specimen. (A, B, C) braincase with jaws, visceral arches and vertebrae attached from both lateral sides and dorsally, (D) braincase with jaws attached. Arrows point to the anterior side. Scale bar= 10 cm.

For documentation purposes, the braincase was first photographed prior to dissection. Subsequent stages of the process, including the original braincase with jaws and visceral arches attached and braincase with jaws attached only, were documented as well. Images presented here were adjusted using Adobe Photoshop CS5 (version 12.0, Adobe Systems, San José, United States) for colour balance, contrast and labelling.

## 4.2. RESULTS

The braincase of *Lamna nasus* was used to generate high-resolution computed tomography scans of the left inner ear skeletal labyrinth to reveal its inner morphology and shape. The CT scans revealed several features regarding the shape and form of the inner ear; however, certain characters could not be resolved from this reconstruction as resolution was either not high enough or they have been damaged through preservation.



**Fig. 4.** Virtual three-dimensional reconstruction of the left skeletal labyrinth of the inner ear of *Lamna nasus*. (A) Dorsal view, (B) lateral view, (C) posterior view. Amira reconstruction. Scale bar= 1 cm. asc, anterior semicircular canal; ed, endolymphatic duct; lsc, lateral semicircular canal; pa, posterior ampulla; psc, posterior semicircular canal; sac, saccular chamber.

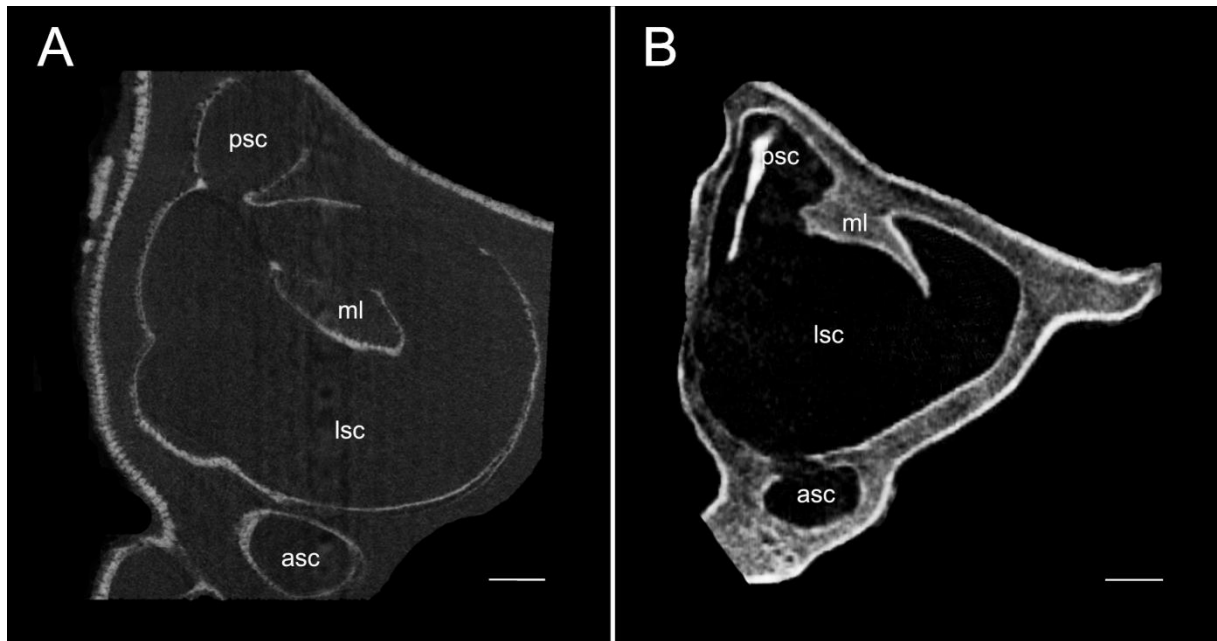
Figure 4 shows the virtual three-dimensional reconstruction of the left inner ear in lateral, dorsal and posterior views. The skeletal labyrinth is enclosed by the optic

capsule. The dorsal surface is connected to the labyrinth region. All three semicircular canals, anterior, lateral and posterior, are oriented close to the vestibular chambers. They are clearly visible and strongly resemble each other in both size and shape. The canals are thick and rather massive, all with a large diameter. The vestibular region is solid and does not possess much structural differentiation. The chambers of the vestibular region are not easily recognizable from the reconstruction, but the saccular chamber is possibly the structure most ventrally of the vestibular chamber (Fig. 4B). Anterior and lateral semicircular canals connect anterior-ventrally but the more prominent connection is not visible as it merges with the general vestibular region and the thicker end of the endolymphatic duct. The endolymphatic duct runs almost vertically, connecting the dorsal surface of the cranium with the vestibular region.

The posterior semicircular canal in *Lamna nasus* forms a rather complete circle and is almost separated from the other regions of the labyrinth which appears to be a feature common among elasmobranchii (Fig. 4C). It is not uniformly thick but becomes slightly thinner when joining with the vestibular region and the endolymphatic duct. This posterior canal duct is rather large and connects large parts of the canal with the vestibular region. The area where the posterior ampulla is situated can be differentiated in the posterior view. The ampullar expansions of the other canals are not visible in this reconstruction. The precise structures such as the crista neglecta or small connections within the chambers are not depicted in the illustrated section.

The general shape of the inner ear of *Lamna nasus*, however, can be characterised as massive and compact, with the semicircular canals constituting most of its anatomy. The semicircular canals are small but big in diameter and the vestibular region is large but not much differentiated.

Additionally to the 3D reconstruction, a 2D reconstruction of the *Lamna nasus* inner ear was obtained in the horizontal plane. To compare the inner ear with another living elasmobranch species, the labyrinth region of an *Isurus sp.* braincase was scanned as well. *Lamna* and *Isurus* are closely related genera within the lamnids and both are known as rapid swimmers. Due to a similar lifestyle and close relationship of both species, it was proposed that the inner ear morphology should be similar as well.



**Fig. 5.** 2D CT scan of the left skeletal labyrinth of (A) *Lamna nasus* and (B) *Isurus sp.*, imaged in the horizontal plane for comparison of the inner ear of both species. Scale bar = 0.5 cm. asc, anterior semicircular canal; lsc, lateral semicircular canal; ml, membranous labyrinth; psc, posterior semicircular canal.

Figure 5 compares slices through the middle section of the inner ear of both *Lamna nasus* and *Isurus sp.*, passing from the dorsal surface of the braincase to the ventral end. General shape of this section is highly similar in both species, indicating a general resemblance of the skeletal labyrinth. Both the anterior and posterior semicircular canal are visible as they have been cut through, showing the round diameter of the canals. The lateral semicircular canal has been cut through entirely, showing the almost uniformly circular shape. Especially in *Lamna nasus*, the canal shape is nearly round. However, features of the vestibular regions and the utricula and saccula chambers were cut through as well, though they cannot be resolved in the scan. The structure in the middle of the lateral semicircular canal in *Lamna* and close to and within the posterior semicircular canal in *Isurus* belongs to remains of the membranous labyrinth that have not been dissolved yet.

### 4.3. DISCUSSION

To our knowledge, no other recent studies have been done on the anatomy of the inner ear of *Lamna nasus*. Maisey (2013) recently published a detailed description of the *Lamna nasus* chondrocranial morphology but did not look into internal features. There are few published descriptions of the skeletal labyrinth of recent sharks or rays to date (e.g. Maisey, 2001; Maisey, 2004b) and comparative studies of both the membranous and skeletal labyrinth morphology within elasmobranchs lack entirely. Thus, ours is the first description and 3D reconstruction of the inner ear of *Lamna nasus* and the first to investigate the shape of the inner ear within lamnids.

This present work illustrates how internal morphologies of the cranium can be revealed and described in modern sharks using micro-computed tomography. High-resolution CT scans provide a rather new tool to investigate the inner ear morphology of elasmobranchs and other fish. While CT scanning has been a well used procedure to infer the inner ear morphology and shape of the semicircular canals of mammals for some time (Spoor et al., 2002; Spoor et al., 2007; Billet et al., 2012; Pfaff et al., 2015), including insights in the locomotion mode of extinct species using the skeletal labyrinth morphology preserved in fossils, it has only been used scarcely in elasmobranchs (Maisey, 2001; Maisey, 2004b). CT scanning allows imaging of morphological details of the inner ear without destroying the material. Fossils can therefore be examined in a non-invasive fashion. Additionally, there is no major preparation needed and the material can be used again for further investigation. CT scans can be further reconstructed three-dimensionally and these images can then be used for additional morphological analyses or measurements.

As the inner ear and its features, notably the membranous labyrinth, are responsible for an animal's orientation by detecting linear velocity and angular acceleration among others, there has been increasing emphasis on the study of the inner ear anatomy to infer correlations of the inner ear with the mode of locomotion and agility: Thus, with the advantage of CT scanning, many aspects of the labyrinth morphology and shape have been studied intensely. Correlations between semicircular canal morphology, size, and orientation and the locomotion mode and behaviour have been inferred from studies on mammals and birds mainly (Spoor et al., 2002; Spoor, 2003; Spoor et al., 2007; Cuthbertson et al., 2015; Pfaff et al., 2015).

A small curvature of the semicircular canal is thought to be congruent with sluggish head movements while a large, thin canal represents highly manoeuvrable species (Spoor et al., 2007; Billet et al., 2012). A correlation between size of the head and size of the inner ear system has implications on the angular head movements but not necessarily on the sensitivity (Spoor, 2003; Cuthbertson et al., 2015). Sensitivity of the inner ear correlates with locomotion mode as well, and smaller canals may be adapted to receiving less sensitive information. Flying and gliding mammals show less sensitive inner ears to better process the large amounts of information into the ear during moving, as do cetaceans (Spoor et al., 2002; Paff et al., 2015). However, these investigations focussed on terrestrial species only. Aquatic animal studies are rare and have yet to examine one important difference: Living in the water poses different challenges to an animal's body and movements as gravitation energy does not play an important role (Spoor et al., 2002). Locomotion with all its implications has to be adapted to this medium.

Spoor et al. (2002) reported differences in the semicircular canal systems of extant cetaceans compared to other mammals and the terrestrial ancestors of modern cetaceans. Canal arc sizes are about three times smaller than in other mammals to reduce the sensitivity of the whole system. Spoor and colleagues argued that this is to match the high levels of uncompensated angular motion cetaceans display with their characteristic fast body rotation behaviour.

Mosasaurs are extinct vertebrates from the Late Cretaceous which have secondarily adapted back to the aquatic medium (Cuthbertson et al., 2015). A new study now published the first description of the skeletal labyrinth in *Plioplatecarpus peckensis*, with implications on the locomotor behaviour from labyrinth size and both size and shape of the three semicircular canals (Cuthbertson et al., 2015). The size of the labyrinth relative to the head size does not seem to have implications on sensitivity in this species. However, the three semicircular canals are tall and highly arched indicating that *P. peckensis* may have been most sensitive to the pitch axis of rotation.

Besides cetaceans and mosasaurs, inner ear and semicircular canal shape have yet to be investigated in extant and extinct aquatic vertebrates. Furthermore, both cetaceans and mosasaurs have both secondarily adapted to the aquatic environment again, while elasmobranchs primarily inhabit the aquatic realm. The degree to which



correlations from secondarily aquatic vertebrates can be used to imply on primarily aquatic species remains unresolved for now. It has been proposed that large semicircular canals indicate slow turning speeds as fish like rays, skates or seahorses display (Young, 1981). Rapid swimmers, mostly predators, by contrast possess narrow canals and the external semicircular canal has a rather small internal radius, indicating high manoeuvrability (Young, 1981). However, comparisons regarding these presumptions have never been made until now, therefore this remains highly speculative.

The *Lamna nasus* skeletal labyrinth is characterised by its massive, compact shape. The semicircular canals are broad and thick, with the lateral semicircular canal having a big internal radius, but rather small in size. Thus, according to Young (1981) this would indicate to some extent a species with slow turning speeds. Given the knowledge that porbeagles are fast swimming sharks and closely related to *Isurus*, containing the fastest swimming shark to date, this result contradicts parts of Young's assumption. As there are no comparisons using actual data to our knowledge, elasmobranch inner ear morphology might have also been subjected to other selection pressures and the aquatic medium might have led to changes in the way equilibrium and balance account for the locomotion within the inner ear.

Maisey (2004a) described the morphology of the braincase and internal structures of the broadnose sevengill shark, *Notorynchus cepedianus*, and reconstructed the skeletal labyrinth region virtually. Semicircular canals of *Notorynchus* are considerably larger and thinner than in our *Lamna nasus* specimen. The same can be noted for the vestibular region. *Notorynchus* is considered a benthic, neritic and plesiomorphic elasmobranch and inhabits mostly the bottom waters of continental shelves (Compagno, 1984). This indicates that this species should display features rather differently from the fast swimming porbeagle, although they do actively increase speed for hunting. Morphologies of both species do differ significantly and this could have first implications on correlations between the inner ear morphology and locomotion behaviour. Another well studied example of shark anatomy is *Squalus acanthias* where silicone endocasts of the inner ear have been made by Schaeffer (1981). *Squalus* is another benthopelagic shark, usually found near the bottom (Compagno, 1984), and skeletal labyrinth morphology reveals very thin and large semicircular canals that differ from *Lamna nasus* significantly as well. Studies

on the skeletal labyrinth of fast swimming sharks or lamnids are not available to date. We additionally investigated an *Isurus sp.* inner ear to be able to compare two closely related species that display similar locomotion behaviours. Unfortunately, there was only time for 2D scans for comparison, but nevertheless the shapes of both inner ears, especially the thickness of anterior and posterior canals as well as the shape of the lateral canal, closely resembled each other, giving us further support for the skeletal labyrinth shape of fast swimming sharks. Additionally, smaller semicircular canals in sharks may have a similar impact on sensitivity as has been shown in cetaceans where this likely accounts for the high levels of uncompensated angular motion (Spoor et al., 2002). Thus, from our investigations there may be correlations between the shape of the canals and the locomotion of elasmobranchs such as: Large semicircular canals with a thin canal diameter account for bottom-dwelling and slow swimming. Small semicircular canals with a thick canal diameter and a very broad lateral semicircular canal could indicate fast swimming predators. However, further research has to be done using a wider spectre of different taxa known for different locomotion modes to draw a significant correlation between shape and locomotion behaviour in elasmobranchs and fish in general.

Nonetheless, when drawing correlations between skeletal labyrinth features and locomotion mode and behaviour, there is always the debate about how closely skeletal and membranous labyrinth morphologies conform. Maisey (2001) concluded that, based on the comparison of CT scanned skeletal labyrinths to known features of the membranous labyrinth in two recent sharks, *Squalus acanthias* and *Notorynchus cepedianus*, the skeletal labyrinth morphology of these sharks shows a high similarity to the membranous labyrinth morphology. On the other hand, mechanical sensitivity of the inner ear depends on features other than simply the shape and dimensions of the inner ear. Morphological properties such as the lumen size of ducts or the dimensions of the ampullae are very difficult to infer from skeletal labyrinths and need close examinations of the membranous structure (Spoor et al., 2003). Further comparisons of both skeletal and membranous labyrinth features to determine the degree of similarity in extant animals could help to resolve this question and further encourage investigations of skeletal labyrinths in fossils to infer information on the lifestyle and locomotion of extinct species.

The results of this study highlight the importance of further investigations of the skeletal labyrinth region in extant elasmobranchs using high-resolution computed tomography. Correlations between inner ear shape and semicircular canal form with locomotion mode have to be established to give insights into equilibrium and balance functioning in different elasmobranch taxa. Contrasting data from extant species may also give implications on the locomotion mode and behaviour of extinct elasmobranchs to cast further light on the evolution of and specialisation of Chondrichthyans. Furthermore, this will ultimately allow us to better resolve the evolution of the inner ear system and phonoreception in gnathostomes in general.

## 5. PART B: TOOTH DEVELOPMENT AND STRUCTURE

The evolution of the vertebrate jaw and teeth is considered to be a crucial evolutionary step in vertebrate history, allowing the occupation of a new range of ecological niches by actively feeding at the top of the food chain (Manzanares and Nieto, 2003; Gai and Zhu, 2012). Teeth became the tool to pierce and cut through prey, and structures evolved to strengthen the teeth and ensure penetration of animal tissue by predators (Frazzetta, 1988; Manzanares and Nieto, 2003). Besides mammals, fish and particularly Chondrichthyans display a wide variety of teeth shapes and functions, believed to reflect dietary preferences (Frazzetta, 1988; Whitenack et al., 2011).

Within Chondrichthyes, especially elasmobranch teeth are made up of a complex structure of three layers: the outer enameloid layer, the inner dentine layer and the basal osseous tissue layer (Goto, 1991; Kesmez et al., 2004). Teeth of elasmobranchs can be divided into two distinct structural types: orthodont and osteodont histotypes (Compagno, 1988; Moyer et al., 2015). While orthodont teeth maintain a pulp cavity throughout the development and show the characteristic cavity still in the functional teeth, osteodont teeth are gradually filled with an osteodentine tissue during development (Compagno, 1988; Moyer et al., 2015). Within elasmobranchs, sharks show a distinctive tooth organization into rows and files, where each tooth file consists of both functional and replacement teeth (Botella et al., 2009). Shark teeth display a great diversity of shapes and structural characteristics that correlate with the mechanics of cutting during feeding (Fazzetta, 1988; Whitenack et al., 2010; Ferrara et al., 2011). However, there are two general shape types that can be differentiated: broad, serrated teeth such as those of the great white shark to bite flesh parts out of large prey and long, pointy or awl-shaped teeth to grab fast moving fish (Fazzetta, 1988; Whitenack et al., 2010; Ferrara et al., 2011). Most lamniform sharks possess a distinctive dentition pattern, the so-called 'lamnoid tooth pattern'. This pattern consists of a heterodont dentition with well differentiated teeth in the jaws according to their formation in the anterior and posterior dental bullae. Anterior teeth are usually enlarged and separated from the lateral teeth by a gap or a small intermediate tooth in the upper jaw. All members of the Lamnidae show this lamnoid tooth pattern to a certain extent, although it is not as obvious in *Carcharodon carcharias* (Compagno, 2001; Shimada, 2002).

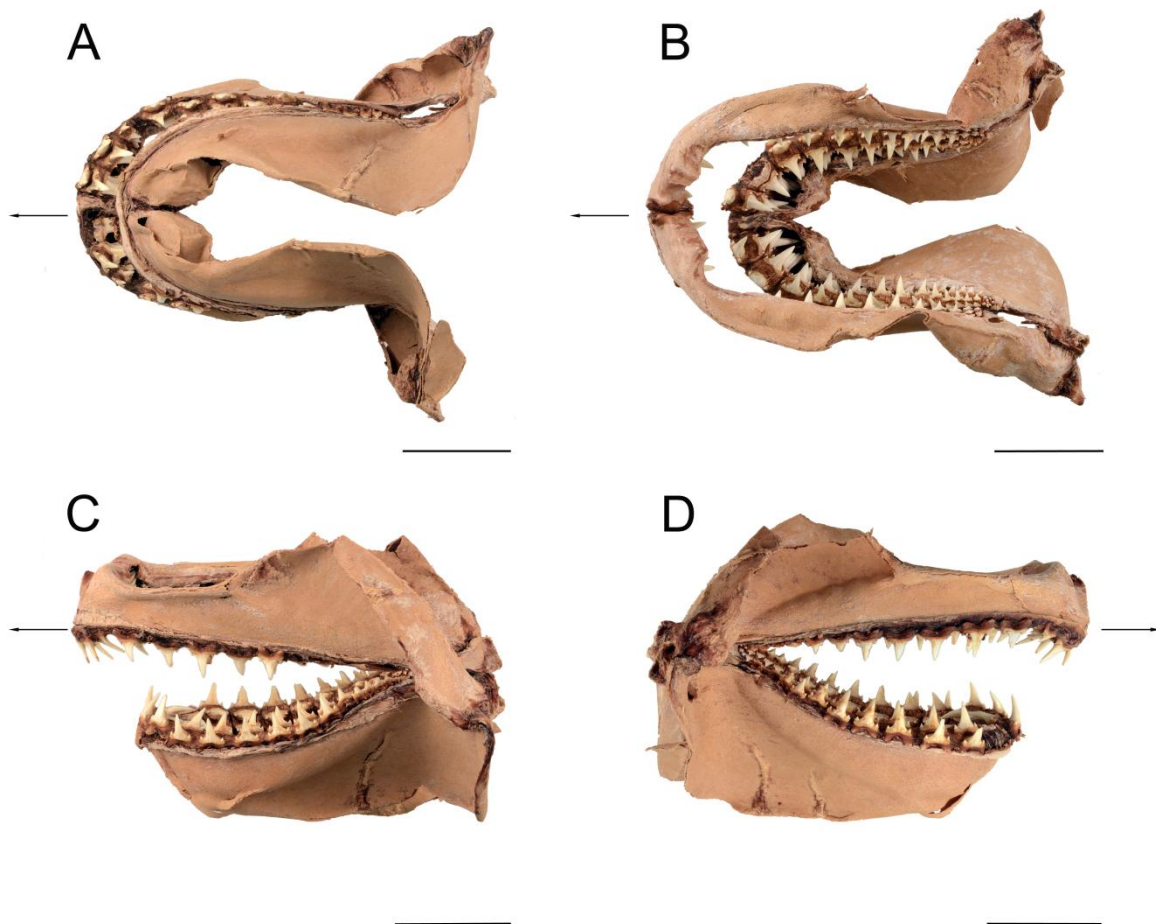
Most Chondrichthyans share the common characteristic of continuously replacing their teeth throughout their lifetime (Williams, 2001, Botella et al., 2009). The replacement allows sharks to retain their feeding and hunting behaviour and dominate the aquatic food chains as top predators. As tooth bases of lamnid sharks do not overlap, dentition can be replaced in each row individually (Compagno, 1988; Shimada, 2002). Lamnidae all have a large crescentic mouth filled with relatively few but impressively large teeth (Compagno, 2001). Teeth of the mackerel shark, *Lamna nasus*, are characterized by having a straight, triangular cusp (up to 2 cm high) and a broad base, a pair of low cusplets separated from the base of the cusp and an overhanging base of the labial face of the crown compared to the labial face of the root with a prominent bulge (Cappetta, 2012).

In this part, the tooth pattern and development of the mackerel shark, *Lamna nasus*, is investigated using high-resolution computed tomography ( $\mu$ CT). 2D stacks of the upper and lower jaw allow us to determine the amount of functional and replacement teeth within a tooth file and the structural development of the teeth within the dental bullae.

## 5.1. MATERIAL AND METHODS

We prepared both the upper and lower jaws and teeth of a *Lamna nasus* specimen for study of the tooth development and structure. Details regarding preparation, storage and origin of the whole braincase were already described in Part A.

The jaws were soaked in diluted hydrogen peroxide to facilitate the removing of soft tissue. As this did not seem to facilitate removal, jaws were additionally soaked in warm water and then manually dissected using scalpels to remove as much soft tissue as possible before scanning. After the scanning procedure, jaws were again soaked in hydrogen peroxide and then dried for storage (Fig. 6).



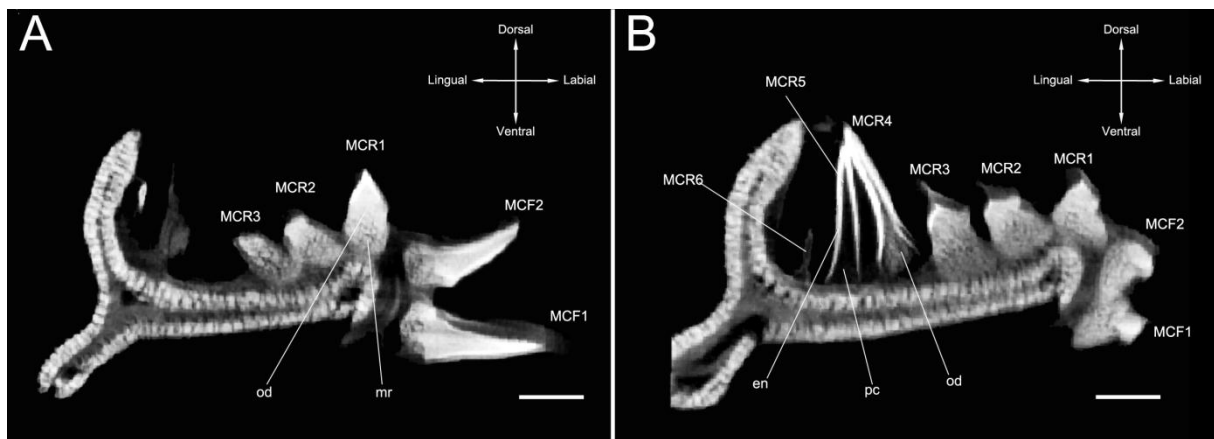
**Fig. 6.** Upper and lower jaws of the *Lamna nasus* specimen after drying. (A) Ventral view, (B) dorsal view, (C, D) lateral views. Arrows point to the anterior side. Scale bar= 5 cm.

The jaws were investigated by micro-CT using the Vienna microCT-Lab-Viscom X8060 with a XT9190-THP X-ray tube at the Department for Anthropology at the University of Vienna, Austria. Scanning at the Vienna microCT-Lab enabled us to obtain images of the entire jaw and dentition. Unfortunately, due to moving during the scanning procedure, only parts of the scans were taken for further investigation. Nevertheless, we were able to use images from both upper and lower jaws. CT-Scanning of the *Lamna nasus* jaws was conducted using the following visual arrangements: 80µm voxel size (resolution equivalent), 120 kV source voltage, 300 µA source current, copper 0.5mm filter and 1400ms exposure time.

Teeth were designated following the code specification of Moyer and colleagues (2015), with some changes: As the position of the tooth file within the jaw is of minor interest in this investigation, teeth will be designated to either upper jaw using PC (palatoquadrate cartilage) or the lower jaw using MC (Meckel's cartilage). Position within the file is indicated by either F for functional tooth or R for replacement tooth together with the subsequent number. 2D Images from µCT scanning presented here were adjusted using Adobe Photoshop CS5 (version 12.0, Adobe Systems, San José, United States) concerning colour balance, contrast and labelling.

## 5.2. RESULTS

Investigations of the jaws and teeth in *Lamna nasus* were made using high-resolution CT Scanning. 2D reconstructions from the CT data show the tooth arrangement in the lower jaw, with all teeth placed alongside the Meckel's cartilage (Fig. 7). Dense structures appear in brighter shades compared to less dense tissues in darker shades. *Lamna nasus* teeth show a smooth surface and a pointy, awl-like shape. Each tooth file contains a total of eight teeth in both lower and upper jaws, with two functional teeth and six replacement teeth of various stages, with the youngest tooth only just developed.



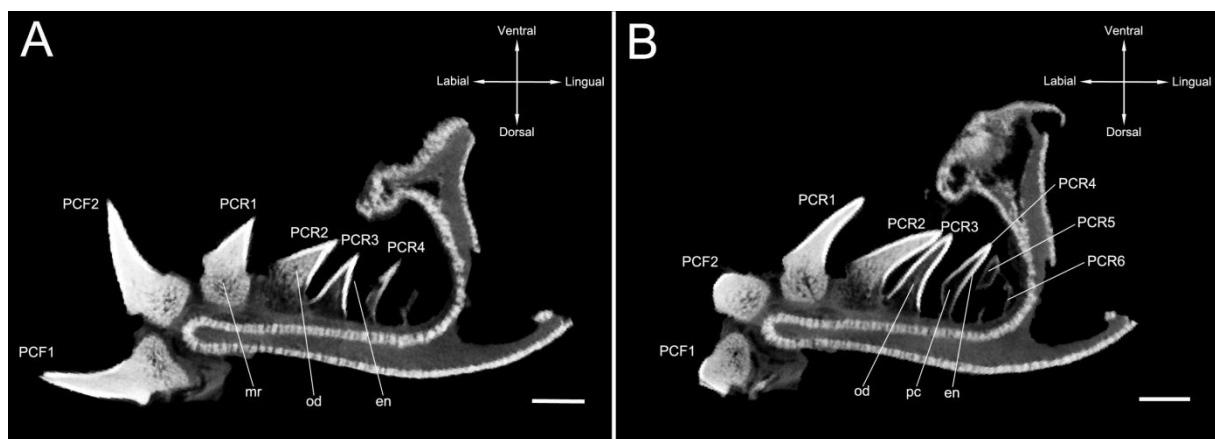
**Fig. 7.** 2D digital CT scans from the lower jaw of *Lamna nasus*. Tooth file showing the number of teeth, teeth stages and development. Scale bar = 0.5 cm. en, enameloid; mr, mineralized root; od, osteodentine; pc, pulp cavity.

In the youngest two teeth, the enameloid layer of the crown is already present, even though it is very thin in MCR6 (Fig. 7B). The formation of the enameloid layer appears to develop from the tip of the crown downwards, towards the root, as can be seen in MCR5. The pulp cavity is prominent in both teeth, but is not easily visible in the youngest tooth and a root is not visible in both MCR6 and MCR5. Osteodentine tissue cannot be seen in these early stages. MCR4 shows first signs of tissue within the pulp cavity, indicating a developing osteodentine layer. The root appears to be still absent in this tooth or just starting to develop. However, root formation clearly does not start in the earliest stages of tooth development. Figure 7A illustrates the tooth stages and development of the 5 older teeth. MCF1 and MCF2 show the fully developed stages of *Lamna nasus* teeth, where a prominent enameloid crown can be



seen and the pulp cavity is completely filled with osteodentine and mineralized as well as the root. However, stages MCR3, MCR2 and MCR1 are difficult to examine in this lower jaw.

2D CT data of the upper jaw show a better resolved development of the intermediate tooth stages (Fig. 8). The early stages of upper tooth development seem to be identical to the lower jaw development, however, the pulp cavity in PCR4 is still rather hollow, with only very little signs, if any, of osteodentine (Fig. 8B). The intermediate stages of tooth development are clearly visible and distinguishable in the upper jaw though: PCR3 displays a partially filled pulp cavity with definite unmineralized osteodentine. The root is difficult to detect in PCR3 but prominent in MCR3 of the lower jaw. The PCR2 shows a well-filled pulp tooth with a root that appears to be partially unmineralized still (Fig. 8A). PCR1 and both functional teeth PCF1 and PCF2 appear to be fully developed: the pulp cavity is entirely filled with osteodentine which appears to be mineralized together with the root structure.



**Fig. 8.** 2D digital CT scans from the upper jaw of *Lamna nasus*. Tooth file showing the number of teeth, teeth stages and development. Scale bar = 0.5 cm. en, enameloid; mr, mineralized root; od, osteodentine; pc, pulp cavity.

These results show how tooth development is conducted in *Lamna nasus*: First, the enameloid crown forms in the newly developing tooth around the hollow pulp cavity. In the youngest tooth, this enameloid layer is rather thin and incomplete compared to later stages. With subsequent growth, the root becomes visible while the pulp cavity starts to fill with osteodentine, hence, exhibiting the osteodont histotype. During

further development, the pulp cavity disappears as the teeth are completely filled with tissue and mineralization of the teeth for strength is more and more visible. Structural mineralization of osteodentine is initiated in the crown first before developing in the root structures. The osteodont histotype of *Lamna nasus* becomes more and more apparent with subsequent development of the replacement teeth as the filling of the pulp cavity continues.

### 5.3. DISCUSSION

To our knowledge, this is the first study to use high-resolution micro-computed tomography on the jaws of *Lamna nasus*. The advantages of CT scanning for investigating tissues and inner morphologies have already been highlighted in the discussion of Part A. Another advantage of the study of tooth stages and development, however, is that a series of sections through the jaw and teeth allows moving through a whole tooth file virtually and thus receiving a better understanding of the structures within. Also, one can examine the development stages of all teeth within a file at the same time and stringed together.

Results of tooth development and stages in the upper and lower jaw of *Lamna nasus* indicate an overall uniform development of teeth in the jaws. There was a slight difference in the 2D reconstructions between both jaws regarding the MCR4 versus the PCR4 tooth as osteodentine was readily visible in MCR4 while pretty much absent in PCR4. Also, the presence of a root is difficult to detect in PCR3 while easily observable in the counterpart MCR3. One has to take into account though, that 2D reconstruction images may not show all details of the teeth. Additionally, moving of the jaw during scanning complicated the reconstruction of the jaw. It is therefore quite possible that osteodentine tissue was not detected during scanning but still present in the PCR4 tooth of *Lamna nasus*. Cartilage tissue in general is difficult to visualize with micro-CT without preparation via staining compared to bony tissues. Small changes in tooth structure and stage may therefore need additional three-dimensional reconstruction to be able to distinguish them from.

Moyer and colleagues (2015) applied micro-CT imaging to compare lower jaw teeth structure and development of the orthodont blue shark, *Prionace glauca*, and the osteodont great white shark, *Carcharodon carcharias*. We find our investigations very similar to theirs in regards to the osteodont histotype as we only studied this one. As both *Lamna nasus* and *Carcharodon carcharias* belong to the same family, the Lamnidae, we expected a certain similarity when it comes to tooth development. Of course, they differ regarding the general tooth shape: While *Carcharodon carcharias* possesses broad, serrated teeth to bite out chunks of flesh of its prey, *Lamna nasus* uses its narrow, pointy teeth to efficiently grab fast swimming fish. However, tooth development, file size and overall structure during subsequent tooth stages is rather identical. Minor differences that we found include PCR3, MCR4 and PCR4 root

stages: In these teeth, a root is not distinguishable in our images of *Lamna nasus*, while Moyer and colleagues (2015) report an incomplete root in the 4<sup>th</sup> replacement teeth and a complete, unmineralized one in the 3<sup>rd</sup> placement teeth. However, MCR3 displays a definite root structure, congruent with their findings. *Carcharodon carcharias* displays two functional teeth that are both fully filled and have a fully mineralized root while roots in the replacement teeth are never completely mineralized. *Lamna nasus* on the other hand displays this structural morphology in both functional teeth and PCR1/MCR1. Both species appear to develop a total of eight teeth in each tooth file. Moyer et al. only investigated the lower jaw of *Carcharodon carcharias*, so we cannot compare whether there might be changes in the development between palatoquadrate cartilage and the Meckel's cartilage.

Moyer and colleagues (2015) additionally proposed that the difference between *Prionace glauca* and *Carcharodon carcharias* regarding the amount of teeth per file might be linked to faster rates of tooth loss and replacement in *Carcharodon*. As different food sources might put different mechanical stresses on jaws and teeth, feeding on large prey such as marine mammals could result in higher tooth loss rates in *Carcharodon*. However, *Lamna nasus* displays the same amount of teeth per file and can be compared to *Prionace glauca* when it comes to food sources as both are primarily piscivorous and feed on fast swimming fish (Compagno, 1984; Joyce et al., 2002). Thus, the amount of teeth per file does not necessarily have to correlate with tooth loss and replacement and the food source per se but might contain a phylogenetic and thus systematic signal.

## 6. CONCLUSION

*Lamna nasus* travels through the water column on continental shelves and in the open ocean as a pelagic predator, its main food source largely including fast swimming fish. Specialisations of the inner ear system according to this lifestyle could be detected in computed tomography scans of the brain capsule. The shape of the skeletal labyrinth revealed a suite of unusual features compared to the labyrinths of described benthopelagic elasmobranchs such as *Notorynchus cepedianus* and *Squalus acanthias*. The semicircular canals are small in size and have a thick diameter and the overall structure of the inner ear is rather massive and compact. These features could be indications for a fast swimming locomotion mode in recent sharks. The aquatic medium may also have implications on the form of the skeletal labyrinth in order to account for balance and equilibrium in fish. However, further CT-scans of the otic region in extant and extinct elasmobranchs should be done to increase the number of morphological characters and features known within the skeletal labyrinth region. This way, they can be included in phylogenetic investigations and reveal further knowledge on the evolution of phonoreception in sharks and rays. Nevertheless, inner ear reconstructions of more specimens of Lamniformes are needed to draw further conclusions on the morphology of the inner ear in this order and the functional relationship of the form of the labyrinth and the locomotion behaviour.

The tooth development and structure in *Lamna nasus* has been identified to closely resemble that of *Carcharodon carcharias*, a closely related species within the lamnid family. Strong similarities have been found in both the development of the enameloid layer, the filling of the pulp cavity with osteodentine and the mineralization of the teeth. Whether there is a connection between tooth file size and tooth loss as well as replacement remains uncertain and needs further research. High-resolution CT provides a new approach to investigate tooth patterns, structures and development in the jaws of elasmobranch species.



## 7. ACKNOWLEDGMENTS

Many people have assisted and supported me finishing this master thesis. First of all, I would like to thank Dr. Jürgen Kriwet for his help and encouragement but most of all for providing me with the opportunity to carry out my thesis in his research group and in the field of study that has always interested me the most since childhood. This work would not have been possible without the outstanding help of Dr. Cathrin Pfaff and her knowledge of both CT scanning and inner ear characteristics. Furthermore, I would like to thank the present members of the Evolutionary Morphology Research Group (EvoMoRG) at the Department of Palaeontology for their fast and competent help whenever needed and especially Gerlinde Kaineder for her help with scaling of some of my CT data.

Special thanks go to Martin Dockner for the repeated scanning of the *Lamna nasus* jaw and his patience despite the unstoppable moving of the specimen during scanning. I would also like to thank Franziska Laaber for reviewing large parts of this work despite the stylistic differences between natural sciences and humane sciences. Last but not least, I would like to express my gratitude to my family for their support both mentally and financially through my academic studies at the University of Vienna which would not have been possible otherwise.





## 8. LITERATURE CITED

- Anderson, S. D., and K. J. Goldman.** 2001. Temperature Measurements from Salmon Sharks, *Lamna ditropis*, in Alaskan Waters. *Copeia* 3:794-796.
- Bernal, D., K. A. Dickson, R. E. Shadwick, and J. B. Graham.** 2001. Review: Analysis of the evolutionary convergence for high performance swimming in lamnid sharks and tunas. *Comparative Biochemistry and Physiology Part A* 129:695-726.
- Billet, G., L. Hautier, R. J. Asher, C. Schwarz, N. Crumpton, T. Martin, and I. Ruf.** 2012. High morphological variation of vestibular system accompanies slow and infrequent locomotion in three toed sloths. *Proceedings of the Royal Society B* 279:3932-3939.
- Bone, Q., and R. H. Moore.** 2008. *Biology of fishes*, pp. 290-296. Taylor & Francis Group, Abbingdon, UK.
- Botella, H., J. I. Valenzuela-Ríos, and C. Martínez-Pérez.** 2009. Tooth replacement rates in early chondrichthyans: a qualitative approach. *Lethaia* 42:365–376.
- Burghardt, A. J., T. M. Link, and S. Majumdar.** 2011. High-resolution Computed Tomography for Clinical Imaging of Bone Microarchitecture. *Clinical Orthopaedics and Related Research* 469:2179–2193.
- Campana, S. E., A. J. F. Gibson, M. Fowler, A. Dorey, and W. Joyce.** 2013. Population dynamics of Northwest Atlantic porbeagle (*Lamna nasus*), with an assessment of status and projections for recovery. DFO Canadian Science Advisory Secretariat Research Document 2012/096:i-84.
- Campana, S. E., and W. N. Joyce.** 2004. Temperature and depth associations of porbeagle shark (*Lamna nasus*) in the northwest Atlantic. *Fisheries Oceanography* 13:52-64.
- Campana, S. E., W. Joyce, L. Marks, P. Hurley, L. J. Natanson, N. E. Kohler, C. F. Jensen, J. J. Mello, H. L. Pratt Jr., S. Myklevoll, and S. Harley.** 2008. The Rise and Fall (Again) of the Porbeagle Shark Population in the Northwest Atlantic , pp. 445-461. *In: Sharks of the Open Ocean: Biology, Fisheries and Conservation*. M. D. Camhi, E. K. Pikitch, and E. A. Babcock (eds.).Blackwell Publishing, Oxford, UK.
- Campana, S. E., L. J. Natanson, and S. Myklevoll.** 2002. Bomb dating and age determination of large pelagic sharks. *Canadian Journal of Fisheries and Aquatic Sciences* 59:450-455.

- Cappetta, H.** 2012. Chondrichthyes Mesozoic and Cenozoic Elasmobranchii: Teeth, pp. 183-219. *In: Handbook of Paleoichthyology*, Vol. 3E. H.-P. Schultze (ed.). Verlag Dr. Friedrich Pfeil, München, Germany.
- Carey, F. G., J. W. Kanwisher, O. Brazier, G. Gabrielson, J. G. Casey, and H. L. Pratt, Jr.** 1982. Temperature and Activities of a White Shark, *Carcharodon carcharias*. *Copeia* 2: 254-260.
- Carey, F. G., J. M. Teal, and J. W. Kanwisher.** 1981. The visceral temperatures of mackerel sharks (Lamnidae). *Physiological Zoology* 54:334-344.
- de Carvalho, M.R.** 1996. Higher-level elasmobranch phylogeny, basal squalians, and paraphyly, pp. 35-62. *In: Interrelationships of Fishes*. M. L. J. Stiasney, L. R. Parenti, and G. D. Johnson (eds.). Academic Press, San Diego, USA.
- Compagno, L. J. V.** 1973. . Interrelationships of living elasmobranchs, pp. 15-61. *In: Interrelationship of Fishes*. P. H. Greenwood, R.S. Miles, and C. Patterson (eds.). Academic Press, London, UK.
- Compagno, L. J. V.** 1977. Phyletic Relationships of Living Sharks and Rays. *American Zoologist* 17:303-322.
- Compagno, L. J. V.** 1984. FAO Species Catalogue. Sharks of the world: An annotated and illustrated catalogue of shark species known to date. Part 1 - Hexanchiformes to Lamniformes. FAO Fisheries Synopsis 4:22-111. FAO, Rome, Italy.
- Compagno, L. J. V.** 1988. Sharks of the Order Carcharhiniformes. Princeton University Press, Princeton, New Jersey, USA.
- Compagno, L. J. V.** 2001. Sharks of the world: An annotated and illustrated catalogue of shark species known to date. Volume 2. Bullhead, mackerel and carpet sharks (Heterodontiformes, Lamniformes and Orectolobiformes). FAO Species Catalogue for Fishery Purposes 1:51-125. FAO, Rome, Italy.
- Compagno, L. J. V., D. A. Didier, and G. H. Burgess.** 2005. Classification of Chondrichthyan Fish, pp. 4-11. *In: Sharks, Rays and Chimeras, the Status of the Chondrichthyan Fishes. Status Survey*. S. L. Fowler, R. D. Cavanagh, M. Camhi, G. H. Burgess, G. M. Cailliet, S. V. Fordham, C. A. Simpfendorfer, and J. A. Musick (eds.). IUCN/SSC Shark Specialist Group. IUCN, Gland, Switzerland and Cambridge, UK.
- Cuthbertson, R. S., H. C. Maddin, R. B. Holmes, and J. S. Anderson.** 2015. The Braincase and Endosseous Labyrinth of *Plioplatecarpus peckensis* (Mosasauridae,

Plioplatecarpinae), With Functional Implications for Locomotor Behavior. *The Anatomical Record* 298:1597-1611.

**David, R., J. Droulez, R. Allain, A. Berthoz, P. Janvier, and D. Bennequin.** 2010. Motion from the past. A new method to infer vestibular capacities of extinct species. *Comptes Rendus Palevol* 9:397-410.

**Douady, C. J., M. Dosay, M. S. Shivji, and M. J. Stanhope.** 2003. Molecular phylogenetic evidence refuting the hypothesis of Batoidea (rays and skates) as derived sharks. *Molecular Phylogenetics and Evolution* 26:215–221.

**Ferrara, T. L., P. Clausen, D. R. Huber, C. R. McHenry, V. Peddemors, and S. Wroe.** 2011. Mechanics of biting in great white and sand tiger sharks. *Journal of Biomechanics* 44:430–435.

**Ferretti, F., R. A. Myers, F. Serena, and H. K. Lotze.** 2008. Loss of Large Predatory Sharks from the Mediterranean Sea. *Conservation Biology* 22:952-964.

**Francis, M. P., S. E. Campana, and C. M. Jones.** 2007. Age under-estimation in New Zealand porbeagle sharks (*Lamna nasus*): is there an upper limit to ages that can be determined from shark vertebrae? *Marine and Freshwater Research* 58:10-23.

**Francis, M. P., and J. D. Stevens.** 2000. Reproduction, embryonic development, and growth of the porbeagle shark, *Lamna nasus*, in the southwest Pacific Ocean. *Fisheries Bulletin* 98:41–63.

**Frazzetta, T. H.** 1988. The mechanics of cutting and the form of shark teeth (Chondrichthyes, Elasmobranchii). *Zoomorphology* 108:93-107.

**Fudge, D. S., and E. D. Stevens.** 1996. The visceral *retia mirabilia* of tuna and sharks: an annotated translation and discussion of Eschricht & Müller 1835 paper and related papers. *Guelph Ichthyology Reviews* 4:1-92.

**Gai, Z., and M. Zhu.** 2012. The origin of the vertebrate jaw: Intersection between developmental biology-based model and fossil evidence. *Chinese Science Bulletin* 57:3819-3828.

**Goldman, K. J., S. D. Anderson, R. J. Latour, and J. A. Musick.** 2004. Homeothermy in adult salmon sharks, *Lamna ditropis*. *Environmental Biology of Fishes* 71:403–411.

**Goto, M.** 1991. Evolutionary Trends of the Tooth Structure in Chondrichthyes, pp. 447-451. *In: Mechanisms and Phylogeny of Mineralization in Biological Systems*. S. Suga, and H. Nakahara (eds.). Springer-Verlag, Tokyo, Japan.

- Heinicke, M. P., G. J. P. Naylor, and S. B. Hedges.** 2009. Cartilaginous fishes (Chondrichthyes), pp. 320-327. *In: The Timetree of Life.* S. B. Hedges, and S. Kumar (eds.). Oxford University Press, New York, USA.
- Helfman, G., B. B. Collette, D. E. Facey, and B. W. Bowen.** 2009. The Diversity of Fishes: Biology, Evolution, and Ecology, pp. 75-78. Wiley-Blackwell, Hoboken, New Jersey, USA.
- Hueter, R. E., D. A. Mann, K. P. Maruska, J. A. Sisneros, and L. S. Demski.** 2004. Sensory Biology of Elasmobranchs, pp. 332-335. *In: Biology of Sharks and Their Relatives.* J. C. Carrier, J. A. Musick, and M. R. Heithaus (eds.). CRC Press LLC, Boca Raton, Florida, USA.
- Jeffrey, N., and P. G. Cox.** 2010. Do agility and skull architecture influence the geometry of the mammalian vestibulo-ocular reflex? *Journal of Anatomy* 216:496-509.
- Jensen, C. F., L. J. Natanson, H. L. Pratt, Jr., N. E. Kohler, and S. E. Campana.** 2002. The reproductive biology of the porbeagle shark (*Lamna nasus*) in the western North Atlantic Ocean. *Fishery Bulletin* 100:727-738.
- Joyce, W. N., S. E. Campana, L. J., Natanson, N. E. Kohler, H. L. Pratt, Jr., and C. F. Jensen.** 2001. Analysis of the stomach contents of the porbeagle shark (*Lamna nasus* Bonnaterre) in the northwest Atlantic. *ICES Journal of Marine Science* 59:1263-1269.
- Kesmez, M., J. Lyon, D. L. Cocke, J. Westgate, H. McWhinney, and T. L. Grady.** 2004. Characterization of the evolutionary aspects of great white shark teeth by x-ray diffraction methods and other supporting techniques. *Advances in X-Ray Analysis* 47:327-337.
- Kriwet, J., and S. Klug.** 2008. Diversity and biogeography patterns of Late Jurassic neoselachians (Chondrichthyes, Elasmobranchii). *Journal of the Geological Society London* 295:55–69.
- Kriwet, J., S. Klug, J. I., Canudo, and G. Cuenca-Bescos.** 2008. A new Early Cretaceous lamniform shark (Chondrichthyes, Neoselachii). *Zoological Journal of the Linnean Society* 154:278-290.
- Maisey, J. G.** 2001. Remarks on the Inner Ear of Elasmobranchs and Its Interpretation From Skeletal Labyrinth Morphology. *Journal of Morphology* 250:236-264.

- Maisey, J. G.** 2004a. Endocranial morphology in fossil and recent chondrichthyans, pp. 139-170. In: Recent Advances in the Origin and Early Radiation of Vertebrates. G. Arratia, M. V. H. Wilson and R. Cloutier (eds.). Verlag Dr. Friedrich Pfeil, München, Germany.
- Maisey, J. G.** 2004b. Morphology of the braincase in the Broadnose Sevengill Shark *Notorynchus* (Elasmobranchii, Hexanchiformes), Based on CT Scanning. American Museum Novitates 3429:1-52.
- Maisey, J. G., and V. G. Springer.** 2013. Chondrocranial Morphology of the Salmon Shark, *Lamna ditropis*, and the Porbeagle, *L. nasus* (Lamnidae). Copeia 3:378-389.
- Manzanares, M., and M. A. Nieto.** 2003. A Celebration of the New Head and an Evaluation of the New Mouth. Neuron 37:895-898.
- Mollen, F. H.** 2010. A partial rostrum of the porbeagle shark *Lamna nasus* (Lamniformes, Lamnidae) from the Miocene of the North Sea basin and the taxonomic importance of rostral morphology in extinct sharks. Geologica Belgica 13:61-76.
- Moyer, J. K., M. L. Riccio, and W. E. Bemis.** 2015. Development and Microstructure of Tooth Histotypes in the Blue Shark, *Prionace glauca* (Carcharhiniformes: Carcharhinidae) and the Great White Shark, *Carcharodon carcharias* (Lamniformes: Lamnidae). Journal of Morphology 276: 797-817.
- Natanson, L. J., J. J. Mello, and S. E. Campana.** 2002. Validated age and growth of the porbeagle shark, *Lamna nasus*, in the western North Atlantic Ocean. Fishery Bulletin 100:266-278.
- Naylor, G. J. P., A. P. Martin, E. G. Mattison, and W. M. Brown.** 1997. Interrelationships of Lamniform Sharks: Testing Phylogenetic Hypotheses with Sequence Data, pp. 199-218. In: Molecular Systematics of Fishes. T. D. Kocher, and C. A. Stepien (eds.). Academic Press, San Diego, United States.
- Nelson, J. S.** 2006. Fishes of the World, pp. 57-60. John Wiley & Sons, Inc., Hoboken, New Jersey, USA.
- Pade, N. G., N. Queiroz, N. E. Humphries, M. J. Witt, C. S. Jones, L. R. Noble, and D. W. Sims.** 2009. First results from satellite-linked archival tagging of porbeagle shark, *Lamna nasus*: Area fidelity, wider-scale movements and plasticity in diel depth changes. Journal of Experimental Marine Biology and Ecology 370:64-74.

- Pfaff, C., T. Martin, and I. Ruf.** 2015. Bony labyrinth morphometry indicates locomotor adaptations in the squirrel-related clade (Rodentia, Mammalia). *Proceedings of the Royal Society B* 282: doi: 10.1098/rspb.2015.0744.
- Platt, C., and A. N. Popper.** 1981. Fine Structure and Function of the Ear, pp. 3-39. *In: Hearing and Sound Communication in Fishes.* W. N. Tavolga, A. N. Popper and R. R. Fay. Springer-Verlag, New York, USA.
- Saunders, R. A., F. Royer, and M. W. Clarke.** 2011. Winter migration and diving behaviour of porbeagle shark, *Lamna nasus*, in the Northeast Atlantic. *ICES Journal of Marine Science* 68:166-174.
- Scacco, U., I. Consalvo, S. Dimuccio, and L. Tunesi.** 2012. On the by-catch of two porbeagle sharks *Lamna nasus* in the central Adriatic Sea. *Marine Biodiversity Records* 5:1-5.
- Shimada, K.** 2002. Dental homologies in lamniform sharks (Chondrichthyes: Elasmobranchii). *Journal of Morphology* 251:38–72.
- Shirai, S.** 1992. Squalan Phylogeny: A New Framework of 'Squaloid' Sharks and Related Taxa. Hokkaido University Press, Sapporo, Japan.
- Shirai, S.** 1996. Phylogenetic Interrelationships of Neoselachians (Chondrichthyes: Euselachii), pp. 9-34. *In: Interrelationships of Fishes.* M. L. J. Stiasney, L. R. Parenti, and G. D. Johnson (eds.). Academic Press, San Diego, USA.
- Sperone, E., G. Parise, A. Leone, C. Milazzo, V. Circosta, G. Santoro, G. Paolillo, P. Micarelli, and S. Tripepi.** 2012. Spatiotemporal patterns of distribution of large predatory sharks in Calabria (central Mediterranean, southern Italy). *Acta Adriatica* 53:13-24.
- Spoor, F.** 2003. The semicircular canal system and locomotor behaviour, with special reference to hominin evolution. *Courier Forschungsinstitut Senckenberg* 243:93-104.
- Spoor, F., S. Bajpal, S. T. Hussain, K. Kumar, and J. G. M. Thewissen.** 2002. Vestibular evidence for the evolution of aquatic behaviour in early cetaceans. *Nature* 417:163-166.
- Spoor, F., T. Garland, Jr., G. Krovitz, T. M. Ryan, M. T. Silcox, and A. Walker.** 2007. The primate semicircular canal system and locomotion. *Proceedings of the National Academy of Sciences of the United States of America* 104:10808–10812.

- Stevens, J., S. L. Fowler, A. Soldo, M. McCord, J. Baum, E. Acuña, A. Domingo, and M. Francis.** 2006. *Lamna nasus*. The IUCN Red List of Threatened Species. Version 2015.2. <[www.iucnredlist.org](http://www.iucnredlist.org)>. [Accessed 16.08.2015].
- Whitenack, L. B., D. C. Simkins, Jr., and P. J. Motta.** 2011. Biology meets engineering: the structural mechanics of fossil and extant shark teeth. *Journal of Morphology* 272:169-179.
- Williams, M. E.** 2001. Tooth Retention in Cladodont Sharks: With a Comparison between Primitive Grasping and Swallowing, and Modern Cutting and Gouging Feeding Mechanisms. *Journal of Vertebrate Paleontology* 21:214-226.
- Winchell, C. J., A. P. Martin, and J. Mallat.** 2004. Phylogeny of elasmobranchs based on LSU and SSU ribosomal RNA genes. *Molecular Phylogenetics and Evolution* 31:214–224.
- Young, J. Z.** 1981. The life of vertebrates, pp. 144-147. Clarendon Press, Oxford, UK.





# CURRICULUM VITAE

## PERSONAL INFORMATION

Name	Lisa Schnetz, BSc
Place of Birth	Tulln, Lower Austria
Citizenship	Austria
E-Mail	lisa.schnetz@hotmail.com

## EDUCATION

Since 08/2013	Master's degree program in ecology, with specialisation in marine biology, University of Vienna, Austria
10/2010 – 08/2013	Bachelor's degree program in biology, with special focus on zoology, University of Vienna, Austria
2002 – 2010	Secondary school with focus on languages, Purkersdorf
1998 – 2002	Elementary School, Purkersdorf

## COURSE WORK

Since 03/2015	Master thesis on 'the Cranial Anatomy of the Porbeagle Shark, <i>Lamna nasus</i> ' at the Department of Palaeontology, University of Vienna, Austria
02/2015 – 03/2015	Lab work as part two of the Marine Ecology Special Course at the University of Vienna, Austria
07/2014 – 11/2014	Study abroad semester at the University of Western Australia as part of the Non-EU Student Exchange Program at the University of Vienna, Austria – focus on Marine Biology and Management courses
06/2014	Part one of the Marine Ecology Special Course at the Ruđer Bošković Institute in Rovinj, Croatia
07/2013	Field course 'Introduction to the Flora and Fauna of Marine Habitats' at the Ruđer Bošković Institute in Rovinj, Croatia
04/2013	Practical course 'Methods of Molecular Phylogenetics: DNA Extraction to Phylogenetic Tree Reconstruction' at the University of Vienna, Austria
02/2013 – 03/2013	Field Work 'GIS Methods, Behavioural Ecology and Diversity of Neotropical Amphibians' at a rainforest

camp in French Guiana, coordinated by the University of Vienna, Austria

## **TECHNICAL SKILLS**

Lab work	Experienced in basic procedures of molecular biology lab work
Amira software	Experienced
Adobe Photoshop	Experienced
MS Office	Advanced skills in MS Word, Excel and PowerPoint
R Programming Software	Basic knowledge
PADI Open Water Diver	38 dives, experience including cold lake waters, Mediterranean Sea and tropical Indian Ocean waters

## **PERSONAL SKILLS**

English	Very experienced, TOEFL Score of 112/120
French	Very experienced
Italian	Basic knowledge
Latin	5 years of experience

## **WORK EXPERIENCE**

2010 – 2014	Summer Internships at Plasser & Theurer Wien, Vienna
11 – 12/2013	Sales Assistant at the Viennese Christmas Markets
11 – 12/2012	
08/2011	Zoo Keeper Internship at the Vienna Zoo
08/2010	Voluntary Work at the Centre for Rehabilitation of Wildlife Animals in Durban, South Africa
07/2009	Internship at Plasser UK in London, United Kingdom